

Neuroprotective role of nerve growth factor in hypoxic-ischemic injury. From brain to skin

A. CHIARETTI¹, B. FALSINI², L. ALOE³, F. PIERRI⁴, C. FANTACCI¹, R. RICCARDI⁴

¹ Department of Pediatric Neuroscience, Catholic University of Rome, Italy;

² Department of Ophthalmology, Catholic University of Rome, Italy;

³ Institute of Neurobiology and Molecular Medicine, National Research Council (CNR), Rome, Italy;

⁴ Division of Pediatric Oncology, Catholic University of Rome, Italy

ABSTRACT

Hypoxic-ischemic injuries (HII) of the brain, optic pathways, and skin are frequently associated with poor neurological and clinical outcome. Unfortunately, no new therapeutic approaches have been proposed for these conditions. Recently, experimental and clinical studies showed that nerve growth factor (NGF) can improve neurological deficits, visual loss and skin damage after HII. Based on these studies, we report the effects of NGF administration in different lesions of the brain, optic pathways and skin. 2.5S NGF purified and lyophilized from male mouse submaxillary glands was utilized for the treatment. NGF administration was started in absence of recovery after conventional and standardized treatment. One mg NGF was administered via the external catheter into the brain, by drop administration in the eye, and by subcutaneous administration in the skin. We treated 4 patients: 2 children with hypoxic-ischemic brain damage, an adult patient with an optic glioma-induced visual loss and a child with a severe crush syndrome of the lower left limb. After NGF treatment, we observed an amelioration of both neurological and electrophysiological function of the brain, a subjective and objective improvement of visual function, and a gradual improvement of ischemic skin lesion. No side effects were related to NGF treatment in all patients studied. Our observation shows that NGF administration may be an effective and safe adjunct therapy in patients with severe HII. The beneficial and prolonged effect on nerve function suggests a neuroprotective mechanism exerted by NGF on the residual viable neurological pathways of these patients.

Key words

Nerve Growth Factor • Hypoxic-Ischemic Injury • Neuroprotection • Neurodifferentiation

Introduction

Hypoxic-ischemic injuries (HII) of the brain, optic pathways, and skin are frequently associated with poor clinical and neurological outcome. Unfortunately, no new therapeutic approaches have been proposed for these conditions. Nerve growth factor (NGF) is a neurotrophin which supports the survival and differentiation of neurons during brain development (Barde, 1994). It has been shown that NGF reduces neural degeneration (Tuszynski et al.,

2004) and promotes peripheral nerve regeneration in rats (Sun et al., 2009). Recently, experimental and clinical studies showed that NGF can improve neurological deficits (Kokaia et al., 1998; Chiaretti et al., 2008), visual loss (Lambiase et al., 2009), and skin damage (Graiani et al., 2004; Aloe et al., 2008; Chiaretti et al., 2002) after HII. NGF protects against neuronal death and exogenous NGF administration has been shown to prevent or significantly reduce acute cholinergic cell loss and severe neurological deficits following brain HII

(Sofroniew et al., 2001). Extensive animal studies have also shown that neurological lesions leading to cognitive and motor disturbances may be counteracted by intracerebral or intraventricular NGF infusion (Fisher et al., 1987; Jonhagen et al., 1998). The over-expression of NGF protein in the brain increases the number of new neurons generated in several forebrain structures and it has been reported an increase of neuronal precursors following intraventricular growth factors administration, such as NGF and brain-derived neurotrophic factor (BDNF) (Zigova et al., 1998). Hypoxic-ischemic damage can be also secondary to several neoplastic diseases of optic pathways, such as craniopharyngiomas and optic gliomas (OGs), that compromise visual function involving both anterior or retro-chiasmatic optic pathways. Exogenous NGF showed neuroprotective effects on the visual system (Micera et al., 2004) due to the presence of NGF receptors on the conjunctiva, cornea, as well as in the retinal pigment epithelium, photoreceptors, and retinal ganglion cells (RGCs) (Carmignoto et al., 1991). The effects of NGF are mediated via uptake by RGCs, anterograde transport along the optic nerve, and release to the postsynaptic geniculate neurons (Caleo et al., 2000). In experimental animal models, intraocular NGF administration keeps RGCs from degeneration after optic nerve transection and ocular ischemia and leads to the rescue of axotomized forebrain cholinergic neurons (Carmignoto et al., 1989; Lambiase et al., 1998), while conjunctivally applied NGF proved to be effective in patients with corneal ulcers and severe glaucoma (Lambiase et al., 2009). It has also been suggested that NGF stimulates the production of vascular endothelial growth factor (VEGF), the most powerful mitogen for endothelial cells that promotes angiogenesis and blood permeability, in peripheral sensory neurons (Calza et al., 2001; Sondell et al., 1999). A consistent number of *in vitro* and *in vivo* studies indicated that fibroblasts and epithelial cells are receptive to the action of NGF and that NGF promotes skin and cornea ulcer healing (Aloe et al., 2008; Lambiase et al., 1998).

In the present study, we report the effects of NGF administration in 2 children with hypoxic-ischemic brain damage, in a patient with OG-visual loss, and in a child with severe crush syndrome of the lower left limb.

Patients and methods

2.5S NGF was purified and lyophilized from male mouse submandibular glands and prepared according to the method of Bocchini and Angeletti (Bocchini and Angeletti, 1969). In all cases we utilized 1 mg of NGF diluted in 10 ml of saline solution and administered once a day for 10 days consecutively. In the first two cases (*Case 1 and 2*), NGF was infused into the brain via the external drainage catheter about 2 months after the hypoxic-ischemic brain injury, when the patients continued to exhibit a poor response to conventional treatment. In *Case 3*, NGF was administered onto the conjunctiva of both eyes. In *Case 4*, NGF was administered subcutaneously. The treatment with NGF was approved by the University's institutional review and ethical board, and by the parents of the infants who provided written informed consent.

Case 1 and 2

The patients, aged 8 and 13 months were admitted to our pediatric intensive care unit (PICU) after prolonged cardio-respiratory arrest and abrupt-onset coma. Mechanical ventilation was started and the haemodynamic stabilization was aimed toward maintaining a normal cerebral perfusion pressure. Because of severe intracranial hypertension, secondary to cerebral edema, the patients underwent external cerebro-spinal fluid (CSF) diversion. Persisting severe comatose state and lacking any other feasible therapeutic approach 2 months after the brain injury, it was taken into consideration the treatment with intraventricular NGF infusion. Neurological evaluation before intraventricular NGF infusion revealed a comatose state and asymmetrical tetraparesis with GCS score of 4 and 5, respectively. Both the patients presented a global aphasia and no response to environmental stimuli. After NGF infusion, the infants showed progressive arousal with recovery of awareness and significant improvement of limb weakness with spontaneous and finalistic movements. Moreover, they became expressive with a good level of understanding and able to communicate by significant amelioration of communicative skills. Finally, when the patients were discharged from the PICU, one month after the NGF treatment, their GCS score were 8 and 9, respectively. Positron emission computer tomography (SPECT) images obtained in the

first patient before NGF therapy, showed multiple cerebral areas with severe perfusion impairment. In the second SPECT scan carried out one month after NGF treatment, an important improvement of regional cerebral perfusion was visually observed in right temporal and occipital cortices, with an increase in radiotracer uptake (20.5% and 17.5% in right temporal and occipital regions, respectively). In the second patient, the first SPECT study performed before intraventricular NGF infusion showed absent ^{99m}Tc -ECD uptake in left frontal, temporal, parietal and occipital regions. A severe hypoperfusion was also observed in left basal ganglia, right thalamus and left cerebellar hemisphere. One month after NGF treatment, the patient underwent a second SPECT scan, showing a marked increase in radiotracer uptake (21% in right superior frontal area and 90% in right occipital region) (Fig. 1 A-D).

Case 3

A 45-year-old woman with anterior pre-chiasmatic OG and severe impairment of visual acuity and visual field from optic nerve atrophy was assessed before and after two NGF treatment courses. At admission neuro-ophthalmologic examination showed bilateral proptosis of 3 mm, normal extrinsic and intrinsic ocular motility. Visual evoked potentials (VEPs) pattern reversal and flicker (8 Hz) stimulation showed severe bilateral amplitude attenuation with an increased time-to-peak. Electroretinograms (ERGs) showed attenuated amplitudes bilaterally of the inner retina-related flicker 1st and 2nd harmonic components. Based on the role of NGF in restoring biochemical and molecular mechanisms of neurons involved in optic pathways disorders, we decided to treat this patient by NGF eye drop administration because of marked and progressive visual loss

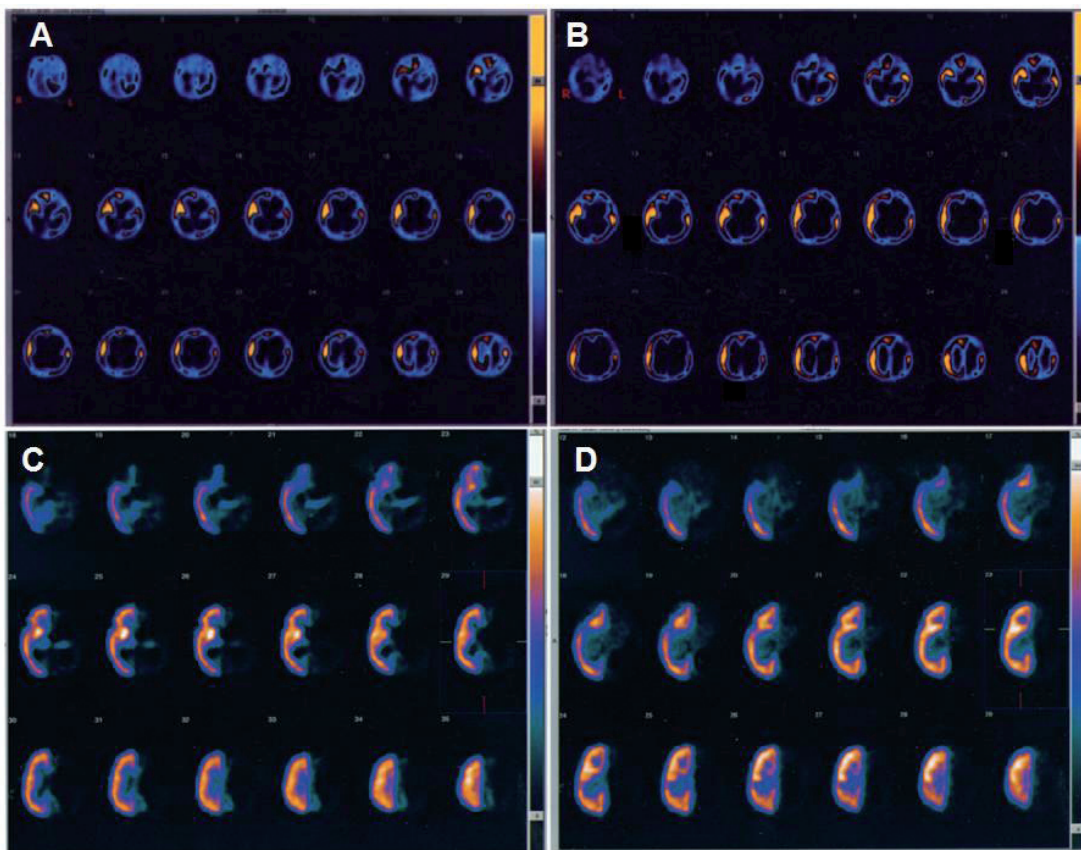


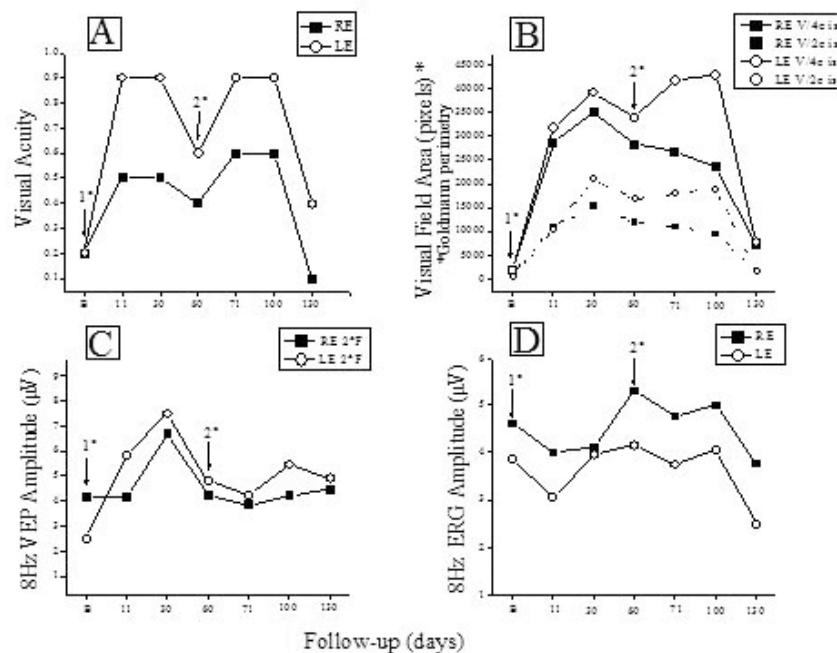
Fig. 1. - SPECT study showing the brain perfusion pattern in the two infants affected by severe hypoxic ischemic brain injury before and after intraventricular NGF administration. Patient 1: A: Before treatment. B: After intraventricular NGF infusion. Patient 2: C: Before NGF infusion. D: After NGF administration. In patient 1, an improvement of regional cerebral perfusion was visually observed in right temporal and occipital cortices, with an increase in radiotracer uptake. In patient 2, a relevant improvement of radiotracer uptake was found in right superior frontal region, right occipital and anterior cingulate cortices.

worsening, no more responsive to conventional and standardized treatment with steroids and mannitol. One mg of NGF, diluted in 5 ml of saline solution (0.2 mg/mL), was administered onto the conjunctiva of both eyes for 10 consecutive days three times a day for each treatment. No ocular or systemic side effects were shown throughout treatment. Brain MRI evaluation, performed at baseline and after 120 days did not show any significant change in tumour volume after NGF treatment. The follow-up was performed by clinical and electrophysiological tests at the end of each treatment, and after further 30 and 60 days. A subjective and objective improvement of visual acuity and visual field (> 3 lines visual acuity; > 40 degrees visual field; Wilcoxon test, $p < 0.01$; magnitude of change > 99 percentile of the test-retest variability for both visual acuity and visual field) (Fig. 2, A and B) allowing her to walk confidently, watch TV, and recover the custom-

ary activities was recorded after 48 hours from the beginning of each treatment. Also VEPs and ERGs showed an improvement after NGF administration ($> 50\%$ increase in VEP amplitude; changes > 99 percentile of the test-retest variability) (Figure 2, C and D). Visual acuity, visual field and VEPs tended, following the improvement, to deteriorate towards baseline values after 60 days from the end of each NGF treatment, suggesting the need to continue NGF administration every 2 months.

Case 4

A 5 year-old child was referred to our PICU with crush syndrome following a road traffic accident. On admission the child showed a severe hypovolemic shock and hypoperfused/hypothermic extremities. Lower limb pulses were just detectable, best in the lower left limb. X-Ray examination confirmed a left femoral dislocated fracture. Traction was applied



Legend: B: baseline; RE = right eye; LE = left eye; 1° = first NGF administration; 2° = second NGF administration; VEP = visual evoked potential; ERG = electroretinogram.

Fig. 2. - Figure shows that, right after the end of each treatment, visual acuity (A) recovered in both eyes by 3-7 lines [significant ($p < 0.05$) increase or decrease is ≥ 2 lines]. Lateral visual fields (B), reported in relative units following planimetric analysis, recovered by several log units of area indicating a main increase in lateral perception of 40 degrees in RE and 35 degrees in LE. VEPs (C) showed an increase in amplitude which paralleled visual acuity improvement. ERGs (D) showed an amplitude enhancement 60 days after the first NGF course and the tended to decline.

to the left thigh, but a few hours after resolution of hypovolaemia, the left lower limb still appeared severely hypoperfused and marbled. Spontaneous mobility was absent even after application of painful stimuli and no arterial pulses were felt. A Doppler ultrasound scan failed to detect any arterial blood flow at the level of the left popliteal artery. At arteriography the superficial femoral artery was interrupted; the interosseal and anterior tibial arteries were seen together with good collateral perfusion. Impaired tactile, heat, and pain sensitivity was detected on electromyography of the left lower limb; absence of voluntary muscle activation with denervated muscle fibres was also present. On day 2, cyanosis and ischemia of the left foot worsened and fasciotomy was performed on the gastrocnemius muscle. Limb perfusion did not improve and two days after fasciotomy the lesions of the heel and toes worsened, with likely extensive foot necrosis. We decided to treat her with topical NGF by NGF

infiltration because of clearer evidence of a border to the ischemic area. One mg of highly purified murine NGF was diluted in 10 ml of normal saline; we administered 1 ml of this solution every day for ten days subcutaneously at the junction between healthy skin and the ischemic area of the heel (Figure 3A, arrows). The lesion gradually improved (Fig. 3B), while untreated areas progressed to necrosis. No side effects were observed during treatment. On day 20 she was discharged in good clinical condition after a femoral osteosynthesis procedure.

Discussion

Previous experimental and clinical studies have shown that hypoxic-ischemic injury determines an increased expression of NGF and other neurotrophic factors in the nervous system, and that the NGF up-regulation plays a pivotal role in protect-

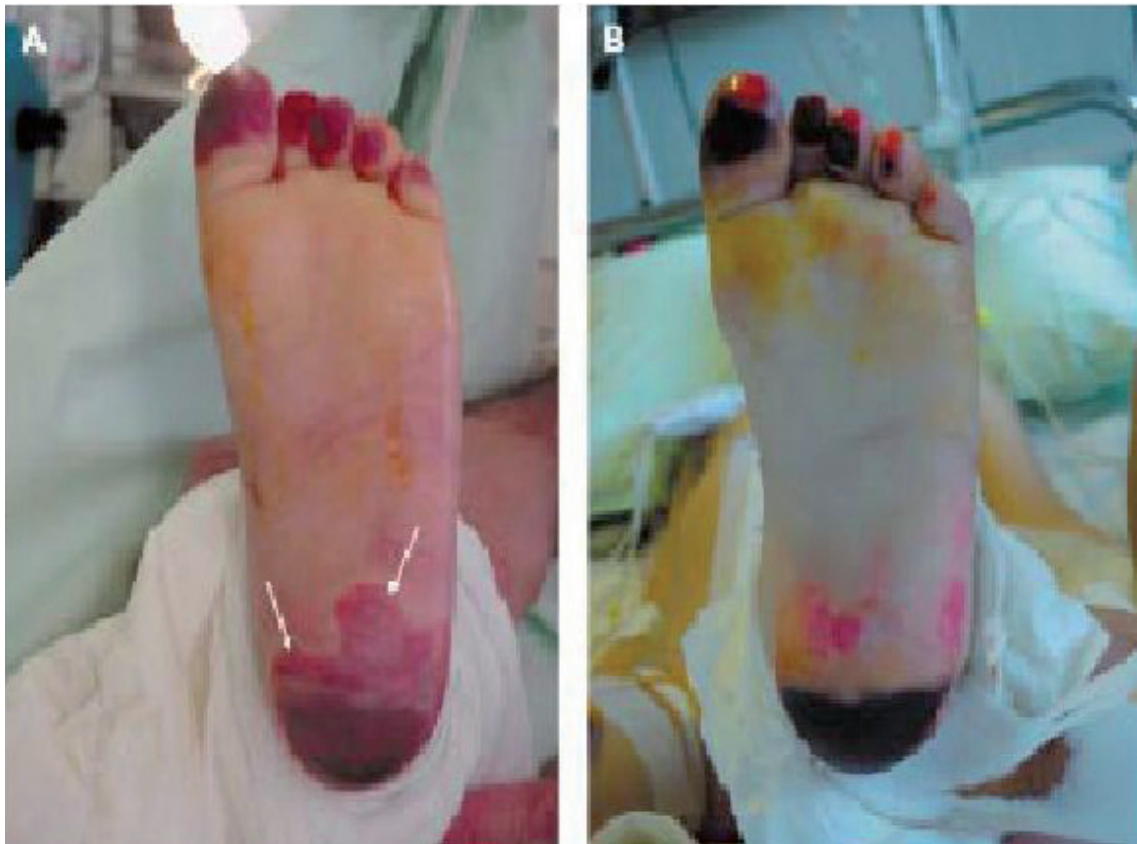

Fig. 3. - A: The ischemic area at the heel, shown by arrows, 48 hours after fasciotomy. B: Evolution of the necrotic area at the heel (pre-escharotomy), with good revascularisation of pre-existing ischemic area after ten days NGF treatment. Ischemic lesions of the toes persist unchanged in size, and formation of bullous lesions can be observed.

ing injured neurons against the biochemical and molecular cascades triggered by ischemic insult (Lindvall et al., 1994). The increased expression of NGF in patients with hypoxic-ischemic damage plays a key role in the response after injury, and may have a beneficial impact on the regenerative capacity of the injured tissues. In *Case 1* and *2* we report the effects of intraventricular NGF infusion in two infants with hypoxic-ischemic brain injury, in which no new therapeutic approaches have been proposed besides the conventional treatment. Before NGF administration, severe comatose state, flaccid tetraparesis, and complete aphasia were apparently stabilized in both patients. After the NGF therapy, both infants showed a significant improvement in motor and cognitive functions, with good recovery of their level of awareness, finalistic movements, and amelioration of their communicative skills. The improvement in the state of consciousness and in the communicative functions is compatible with the hypothesis of NGF-induced enhancement of cholinergic brain functions (Riekkinen et al., 1991). In these patients, serial EEG recordings showed an important reduction of slow-wave activity after the NGF treatment, and a simultaneous increase in higher frequencies, approximating a more normal EEG pattern. Also SPECT imaging showed a significant improvement of cerebral perfusion related to the concomitant increase of NGF levels in the CSF. Intraventricular NGF infusion was followed by an improvement of regional cerebral perfusion and selective neurogenesis was demonstrated by the regional ^{99m}Tc -ECD uptake increase, reflecting a new cerebral tissue viability and cholinergic functions, as previously reported in literature (Lie et al., 2004; Zhang et al., 2005). In *Case 3* we showed that NGF eye-drop administration ameliorated visual acuity, visual field, VEPs and ERGs amplitudes, as indicators of visual loss reversal after NGF treatment. The improvement of VEPs and ERGs suggests molecular events within surviving RGCs leading to a recovery of their physiological responses. It is known that RGCs express NGF receptor (TrkA) and that NGF, binding to TrkA, up-regulates Bcl-2 protein, which protects cells from apoptosis by preventing caspase activation (Coassin et al., 2008). Furthermore, intravitreal NGF delivery to the retina and optic nerve is crucial to the survival of RGCs and for functional recovery of the retina following

ocular ischemia and hypertension in experimental animal models (Carmignoto et al., 1989). Lastly, conjunctivally applied NGF has been shown to reach sharply the retina and optic nerve where this neurotrophin exerts its biological activities. In this patient the electrofunctional changes after NGF administration were immediately followed by clinical improvement. Amelioration of both clinical and electrophysiological parameters lasted for about 60 days after NGF treatment, indicating that NGF effect on optic pathways had a prolonged duration. This prolonged and stable NGF effect may be related not only to a protective activity against neural apoptosis, but also to the formation of new neural pathways, since it is known that NGF promotes neuronal repair and axonal regeneration (Rohrer et al., 1999; Sofroniew et al., 2001). In *Case 4* NGF administration at the junction between healthy skin and the ischemic area of the heel was followed by improvement of vascularisation in a broad area of the heel and necrotic evolution ceased. The beneficial effect of NGF is supported by our observation that there was no improvement of the ischemic lesions of the toes and no decrease in the size of the necrotic area. Moreover, following NGF administration there was good re-epithelisation without any scar formation. Recent studies suggest that angiogenesis is triggered by an increase of NGF, that promotes neuron induced angiogenesis by stimulating VEGF production (Ogunshola et al., 2000). A number of stimuli may induce VEGF expression, including several growth factors, cytokines, hormones, nitric oxide (NO), and hypoxia through hypoxia inducible factor (Ogunshola et al., 2000). The effect of NGF on NO production also supports this hypothesis, because a single NGF injection induces a strong up-regulation of the neuronal isoform of NO synthase (NOS) and of the associated histochemical NADPH-diaphorase reaction. This is followed by VEGF induced angiogenesis and consequently by a reduction NOS expression. These findings suggest that angiogenesis may be regulated through activation of angiogenetic and vasodilatation agents directly produced by neurons and that NGF indirectly stimulates this process. However, the presence of NGF and its receptors in vascular smooth muscle cells suggests that this neurotrophic factor can play a paracrine/autocrine function in the vascular system and that repeated subcutaneous injections of NGF in the ischemic

hindlimb can accelerate the process of revascularisation, by increasing the number of arterioles (Calza et al., 2001). Thus, NGF alone or in combination with other endogenous molecules, can exert its action on endothelial cells and on angiogenic processes (Turrini et al., 2002).

In conclusion, these first observations show that NGF administration may be an effective and safe adjunct therapy in patients with severe hypoxic-ischemic injury of the brain and other tissues and that the beneficial effect on nerve function suggests a neuroprotective mechanism exerted by NGF on the residual viable neurological pathways of these patients.

References

- Aloe L., Tirassa P., Lambiase A. The topical application of nerve growth factor as a pharmacological tool for human corneal and skin ulcers. *Pharmacol. Res.*, **57**: 253-258, 2008.
- Barde YA. Neurotrophins: a family of proteins supporting the survival of neurons. *Prog. Clin. Biol. Res.*, **390**: 1855-1859, 1994.
- Bocchini V., Angeletti P.U. The Nerve Growth Factor: purification as a 30,000 molecular weight protein. *Proc. Natl. Acad. Sci. U.S.A.*, **64**: 787-794, 1969.
- Caleo M., Menna E., Chierzi S., et al. Brain-derived neurotrophic factor is an anterograde survival factor in the rat visual system. *Curr. Biol.*, **10**: 1155-1161, 2000.
- Calza L., Giardino L., Giuliani A., et al. Nerve growth factor control of neuronal expression of angiogenic and vasoactive factors. *Proc. Natl. Acad. Sci. U.S.A.*, **98**: 4160-4165, 2001.
- Carmignoto G., Maffei L., Candeo P., et al. Effect of NGF on the survival of rat retinal ganglion cells following optic nerve section. *J. Neurosci.*, **9**: 1263-1272, 1989.
- Carmignoto G., Comelli M.C., Candeo P., et al. Expression of NGF receptor mRNA in the developing and adult rat retina. *Exp. Neurobiol.*, **111**: 302-311, 1991.
- Chiaretti A., Piastra M., Caresta E., et al. Improving ischaemic skin revascularisation by nerve growth factor in a child with crush syndrome. *Arch. Dis. Child.*, **87**: 446-448, 2002.
- Chiaretti A., Antonelli A., Genovese O., et al. Intraventricular nerve growth factor infusion improves cerebral blood flow and stimulates doublecortin expression in two infants with hypoxic-ischemic brain injury. *Neurol. Res.*, **30**: 223-228, 2008.
- Coassin M., Lambiase A., Sposato V., et al. Retinal p75 and bax over expression is associated with retinal ganglion cells apoptosis in a rat model of glaucoma. *Graefes Arch. Clin. Exp. Ophthalmol.*, **246**: 1743-1749, 2008.
- Fisher A., Victorin K., Björklund A., Williams L.R., Varon S., Gage F.H. Amelioration of cholinergic neuron atrophy and spatial memory impairment in aged rats by nerve growth factor. *Nature*, **329**: 65-68, 1987.
- Graiani G., Emanuelli C., Desortes E., et al. Nerve growth factor promotes reparative angiogenesis and inhibits endothelial apoptosis in cutaneous wounds of Type 1 diabetic mice. *Diabetologia*, **46**: 1047-1054, 2004.
- Jönghagen M.E., Nordberg A., Amberla K., et al. Intracerebroventricular infusion of nerve growth factor in three patients with Alzheimer's disease. *Dement. Geriatr. Cogn. Disord.*, **9**: 246-257, 1998.
- Kokaia Z., Andsberg G, Martinez-Serrano A, et al. Focal cerebral ischemia in rats induces expression of p75 neurotrophin receptor in resistant striatal cholinergic neurons. *Neuroscience*, **84**: 1113-1125, 1998.
- Lambiase A., Rama P., Bonini S., et al. Topical treatment with nerve growth factor for corneal neurotrophic ulcers. *N. Engl. J. Med.*, **338**: 1174-1180, 1998.
- Lambiase A., Aloe L., Centofanti M., et al. Experimental and clinical evidence of neuroprotection by nerve growth factor eye drops: Implications for glaucoma. *Proc. Nat. Acad. Sci. U.S.A.*, **106**: 13469-13474, 2009.
- Lie D.C., Song H., Colamarino S.A., Ming G.L., Gage F.H. Neurogenesis in the adult brain: new strategies for central nervous system diseases. *Annu. Rev. Pharmacol. Toxicol.*, **44**: 399-421, 2004.
- Lindvall O., Kokaia Z., Bengzon J., Elmer E., Kokaia M. Neurotrophins and brain insults. *Trends Neurosci.*, **17**: 490-496, 1994.
- Micera A., Lambiase A., Aloe L., et al. Nerve growth factor involvement in the visual system: implications in allergic and neurodegenerative diseases. *Cytokine Growth Factor Rev.*, **15**: 411-417, 2004.
- Ogunshola O.O., Stewart W.B., Mihalcik V., et al. Neuronal VEGF expression correlates with angiogenesis in postnatal developing rat brain. *Dev. Brain. Res.*, **119**: 139-153, 2000.

- Riekkinen P., Buzsáki G., Riekkinen JrP., Soininen H., Partanen J. The cholinergic system and EEG slow waves. *Electroencephalogr. Clin. Neurophysiol.*, **78**: 89-96, 1991.
- Rohrer B., Korenbrot J.I., LaVail M.M., et al. Role of neurotrophin receptor TrkB in the maturation of rod photoreceptors and establishment of synaptic transmission to the inner retina. *J. Neurosci.*, **19**: 8919-8930, 1999.
- Sofroniew M.V., Howe C.L., Mobley W. Nerve growth factor signalling, neuroprotection and neural repair. *Ann. Rev. Neurosci.*, **24**: 1217-1281, 2001.
- Sondell M., Lundborg G., Kanje M. Vascular endothelial growth factor stimulates Schwann cell invasion and neovascularization of a cellular nerve grafts. *Brain Res.*, **846**: 219-228, 1999.
- Sun W., Sun C., Lin H., et al. The effect of collagen-binding NGF-beta on the promotion of sciatic nerve regeneration in a rat sciatic nerve crush injury model. *Biomaterials*, **30**: 4649-4655, 2009.
- Turrini P., Gaetano C., Antonelli A., et al. Nerve growth factor induces angiogenic activity in a mouse model of hindlimb ischaemia. *Neurosci. Lett.*, **323**: 109-112, 2002.
- Tuszynski M., Blesch A. Nerve growth factor: from animal models of cholinergic neuronal degeneration to gene therapy in Alzheimer's disease. *Prog. Brain Res.*, **146**: 441-449, 2004.
- Zhang G., Zhang L., Logan R., Jung B.P., Yuen D., Ching Hsu J., Eubanks J.H. Decreased expression and impaired function of muscarinic acetylcholine receptors in the rat hippocampus following transient forebrain ischemia. *Neurobiol. Dis.*, **20**: 805-813, 2005.
- Zigova T., Pencea V., Wiegand S.J., Luskin M.B. Intraventricular administration of BDNF increases the number of newly generated neurons in the adult olfactory bulb. *Mol. Cell. Neurosci.*, **11**: 234-245, 1998.