

# Amyotrophic lateral sclerosis and frontotemporal dementia (ALS-FTD)

S. ZAGO<sup>1,2</sup>, B. POLETTI<sup>2</sup>, C. MORELLI<sup>2</sup>, A. DORETTI<sup>2</sup>, V. SILANI<sup>2</sup>

<sup>1</sup> Department of Neurological Sciences, Università degli Studi di Milano, Medical School IRCCS, Fondazione Ca' Granda Ospedale Maggiore Policlinico, IRCCS Istituto Auxologico Italiano, Milan, Italy;

<sup>2</sup> Department of Neurology and Laboratory of Neuroscience, "Dino Ferrari" Center, Università degli Studi di Milano, IRCCS Istituto Auxologico Italiano, Milan, Italy

## ABSTRACT

*There is increasing clinical, imaging and neuropathological evidence that Amyotrophic lateral sclerosis (ALS) represents a multisystem neurodegenerative disease. Neurodegeneration is not restricted to motor neurons, but also includes parts of the brain other than the motor cortex, especially the prefrontal and/or anterior temporal lobe, that contribute to the clinical syndrome. In some cases an evident dementia that resembles frontotemporal degeneration (FTD) was observed. It is now suggested that ALS and FTD are closely related conditions with overlapping clinical, pathological, radiological, and genetic characteristics. The presence of a frontal dementia in ALS has also crucial practical consequences for management of the patients, whose disorder requires critical life decisions for enteral nutrition and respiratory complications. It is our intent to provide a brief overview of the relationships between ALS and FTD.*

## Key words

ALS • FTD • ALS-FTD syndrome

## Introduction

Both cognitive and behavioural complaints within Amyotrophic lateral sclerosis (ALS) were noted more than a century ago (Marie, 1892; Pilcz, 1898; Cullere, 1906; Resegotti, 1907; Fragnito, 1907; Gentile, 1909). Moreover, studies dating back to the 1930s revealed a clear association between ALS-dementia and a frontal lobe degeneration, also with supportive post-mortem histopathological evidence (von Braunmühl, 1932; Wechsler and Davison, 1932; Gozzano, 1936; De Caro, 1941; Tronconi, 1941; Delay et al., 1959; van Reeth et al., 1961). However, these sporadic observations were considered, by the majority of researchers, either as a fortuitous association of two distinct characterized

degenerative diseases, or as the effect of an unusual lesion extension of motoneuron disease beyond the rigorous usual neuropathological areas specific for ALS. As a consequence, the route leading to the acceptance of a cognitive-behavioral involvement in ALS has not been without difficulty. Reading through the ALS diagnostic guidelines defined at Consensus Conference held in El Escorial, Spain, in 1990, it is notable that cognitive alterations represented an exclusion criterion for the diagnosis of ALS (Brooks et al., 1994). It was postulated that the ALS patient remained cognitively undamaged until the terminal stage of the illness. The criteria were renewed in 1998 after updating to accept the presence of cognitive/behavioural impairment in ALS patients (Brooks et al., 2000). In 1994, the Lund and

Manchester Group first used the term frontotemporal dementia (FTD) with motor neuron disease (The Lund and Manchester Groups, 1994).

It is only recently that cognitive and behavioural symptoms in ALS have gained the interest of both clinicians and researchers, finding a rational consensus on terminology, diagnostic criteria, and clinical significance of a range of cognitive abnormalities. In 2007, an expert group convened at the Second International Frontotemporal Dementia in ALS Research Conference in London (Ontario, Canada) where new diagnostic criteria and a new classification system were defined (Strong et al., 2009). This brought order to a chaotic situation in which nomenclature varied and diagnostic criteria showed enormous variations according to the different ALS phenotypes. The connection between ALS and an overt cognitive/behavioural deterioration congruent to FTD, which appears to overlap at several levels, has raised great interest (Lillo and Hodges, 2009). It is noteworthy that the ALS-FTD relationship has brought the research of ALS out of its conceptual and clinical isolation by providing it with a prominent role in the study of neurodegenerative diseases.

### The new classification of cognitive and behavioural disorder in ALS

In 2009, Strong and colleagues articulated new guidelines to direct ongoing investigation of cognitive and behavioural syndromes in ALS (Strong et al., 2009). To define the neuropsychological status of ALS patients a framework based on four different axes was proposed (see Table I).

Axis I is based on the El Escorial criteria proposed in 1998, that includes possible, probable, and definite ALS clinical subtypes. This multidimensional approach incorporates several criteria (Brooks et al., 2000).

The novelty of the classification lies primarily in Axis II with the proposal of five categories with which to classify ALS patients along a continuum: (1) ALS patients cognitively and behaviourally intact; (2) ALS patients with mild cognitive impairments; (3) ALS patients with mild behavioural impairments; (4) ALS with a full-fledged fronto-temporal dementia; (5) ALS with other non FTD-forms of dementia (see Table II). The terms ALS<sub>ci</sub> (ALS with cognitive impairment), ALS<sub>bi</sub> (ALS with behavioural impairment), ALS-FTD (amyotrophic lateral sclerosis-frontotemporal dementia) and ALS non-FTD dementia, are concepts that aim to capture the key differences between the various clinical phenotypes. Axis III indicates the presence, in addition to frontotemporal impairments, of additional non-motoneuronal disease manifestations such as extrapyramidal signs, cerebellar degenerations, autonomic dysfunctions, sensory impairments, and ocular motility abnormalities. The absence of the above indicates a 'pure form', while the presence defines 'complicated forms' with additional pathological motor aspects. Axis IV, instead, provides the search for factors which could modify the course of the disease. Several disease modifiers have been reported in literature associated with longer survival, age at symptom onset (< 45 years), gender (male sex), and site of the disease onset (bulbar or limb).

### ALS mild cognitive impairment and ALS-FTD: a clinical continuum?

Cognitive and behavioural deficits in ALS may appear along a clinical *continuum*, ranging from mild-to-moderate impairment to FTD (Strong et al., 2003). A series of cross-sectional studies have shown that a significant proportion of patients develop an attenuated pattern of cognitive and behavioural difficulties. In the two largest epidemiologic studies so far, the

Table I. - Clinical characterization of ALS based on four primary Axis (from Strong et al., 2009).

|                                                              |
|--------------------------------------------------------------|
| Axis I - Defining the motor neuron disease variant           |
| Axis II - Defining the cognitive and behavioural dysfunction |
| Axis III - Additional non-motor disease manifestations       |
| Axis IV - Presence of disease modifiers                      |

|                                                                                           |
|-------------------------------------------------------------------------------------------|
| Table II. - Cognitive and behavioural characterization of ALS (from Strong et al., 2009). |
| ALS pure - Absence of any change of the fronto-temporal axis                              |
| ALSci - ALS with a mild cognitive impairment                                              |
| ALSbi - ALS with a mild behavioural impairment                                            |
| ALS-FTD - ALS with fronto-temporal dementia                                               |
| Comorbidity of ALS with other non FTD forms of dementia                                   |

occurrence of mild cognitive impairment has been reported in 36% and 51% respectively of patients with ALS (Massman, et al., 1996; Ringholz et al., 2005). Murphy et al. (2007) identified a subtype of ALS patients revealing mild behavioural changes without cognitive dysfunction. According to the diagnostic guide proposed by Strong et al. (2009), the ALSci and ALSbi acronyms refer to patients with cognitive limitations or changes in affect and social behaviour that do not meet the criteria for dementia. Raaphorst et al. (2010), in a meta-analysis aiming to clarify the magnitude and pattern of cognitive impairment in non demented ALS patients, analyzed 48 neuropsychological studies: sixteen were eligible for inclusion in the meta-analysis that further confirmed that non-demented ALS patients may suffer from decreased cognitive abilities, further corroborating previous observations that ALS is not solely confined to the upper and lower neuron tracts *per se*. Apparently, cognitive domains subserved by the non motor zone in the cerebral cortex resulted affected in ALS patients as well.

The mildest impairments reflect putative frontal dysfunction but must not be considered synonymous with the more severe and disabling dementia of the frontal lobe type (Wolley and Katz, 2008). A number of ALS patients, estimated between 3% to 10%, or even as high as 52%, will develop severe cognitive/behavioural deficits which fulfill the criteria for FTD (Neary, Snowden and Mann, 2000; Lomen-Hoerth et al., 2003). Whether ALS and cognitive deficit fall into a single disease spectrum or represent a distinct clinical syndrome is debatable. However, a *continuum* for cognitive abnormalities in patients with ALS has been proposed (Talbot et al., 1995; Lomen-Hoerth et al., 2002; Neary et al., 2000). Fig. 1 represents the hypothetical clinical and physiopathological *continuum* between ALS and FTD.

If FTD reflects the extreme end of a disease *continuum*, with ALSci as the more benign initial manifestation, one should expect a conversion from

ALSci to FTD over time (Murphy et al., 2007). However, a number of longitudinal studies have failed to detect a prominent cognitive deterioration with disease progression (Moretti et al., 2002; Kilani et al., 2004; Abrahams et al., 2005; Schreiber et al., 2005). Strong and colleagues (1999) were the first to address this issue in a follow-up study (6 month time period) in a small cohort of patients who had bulbar-onset. No major changes of cognitive functions were found, and the patient's performance even slightly improved on about half of the measures while it moderately declined on the other half. In contrast, patients who present to ALS clinics with clear FTD show clear progression of dementia along with motor decline. Also a report by Moretti and colleagues (2002) found that among a cohort of patients documented at baseline to have different degrees of cognitive and behavioural impairment, progression was only evident in those initially diagnosed with FTD. Robinson and colleagues (2006) reported declines in cognitive test scores, defined by a 1 standard deviation change, but they did not specify whether performances declined to levels consistent with clinical impairment (i.e., below the 5<sup>th</sup> percentile). From these studies it appears quite clear that progression of the cognitive impairments in ALS needs to be tested in a large series of patients, for more long follow-up periods and with specific attention to possible bias deriving from scores with repeated testing (i.e. 'learning effect').

To corroborate the hypothesis of a continuum between ALS and FTD some researchers have demonstrated the reverse phenomenon. In fact, some FTD patients displayed clinical and pathological degeneration of the anterior horn and the spinal cord (Neary et al., 1998). Post-mortem analysis showed that cells in the anterior horn degenerate and have typical ALS inclusions in FTD patients who had no apparent clinical features of motoneuronal impairment during life (Jackson et al., 1996). Lomen-Hoerth et al. (2002) reported that approxi-

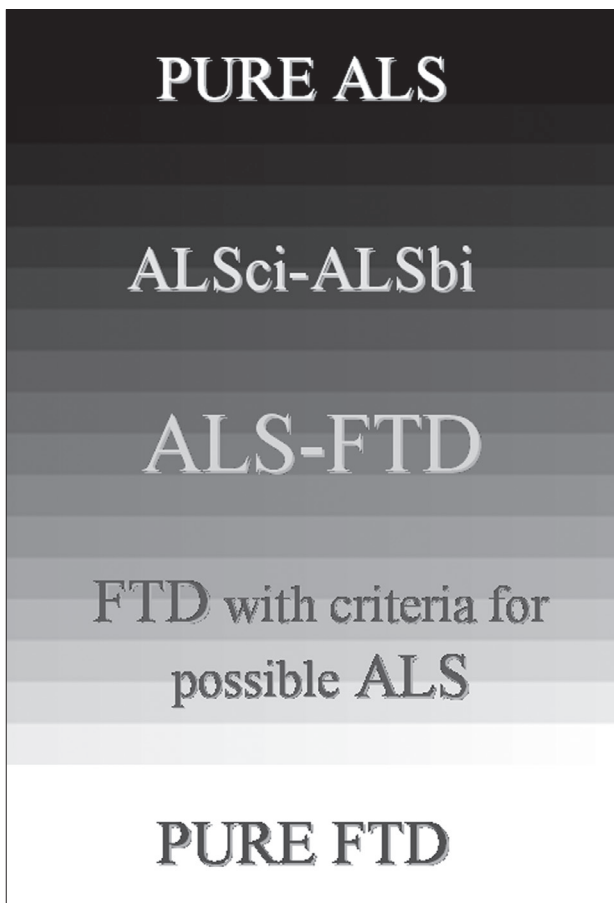

Fig. 1. - ALS and FTD clinical continuum.

mately 14% of patients with FTD developed, over the course of disease, motor alterations and showed instrumental abnormalities on EMG, consistent with the diagnosis of ALS. In addition, about 36% of the patients with FTD show signs of suffering of the first and/or second motor neuron (Lomen-Hoerth et al., 2002). Despite these results no clear reports exist of patients in ALS centers developing clear FTD during the course of motor degeneration (Wolley and Katz, 2008).

### The characteristics of ALS-FTD syndrome

As noted earlier, the most common form of dementia observed in ALS patients is FTD, also known as frontotemporal lobar degeneration (FTDL), although this last term should be properly used to define the neuropathological correlate to the FTD patients (Strong et al., 2009).

Originally associated with Pick's disease, the FTD acronym is actually an overarching term that describes a variable spectrum of impairments characterised by profound changes in personality and altered social conduct, along with prevalent cognitive impairments in executive function, language and semantic knowledge. This cocktail of symptoms reflects different circumscribed atrophies of the prefrontal and anterior temporal neocortex, and possibly an involvement of the rostral limbic system (Boccardi, et al., 2005; Neary et al., 2005). Unlike other dementias, notably Alzheimer's disease, FTD encompasses considerable pathological heterogeneity (Hodges et al., 2004).

A consensus panel posited three major subtypes of FTD on the basis of the clinical profile at presentation, but not on the type of neuropathology: frontal variant frontotemporal dementia (fvFTD); progressive non-fluent aphasia (PNFA) and semantic dementia (SD) (Neary et al., 1998; Hodges and Miller, 2001; Hodges et al., 2004; Neary et al., 2005). In addition, a new variant of PPA, named 'logopenic' has been recognized (Gorno-Tempini et al., 2004; 2011; Grossman, 2010). In particular, three main PPA variants were recognised: non fluent variant PPA, semantic variant PPA and logopenic variant PPA. Fig. 2 summarizes the main FTD subtypes potentially associated with ALS.

### *FTD variants: clinical anatomical features and ALS relationship*

The early manifestations of the frontal or behavioural variant (fvFTD) involve the non cognitive behavioural domain with pervasive alterations in social interpersonal conduct, impaired regulation of personal conduct, emotional blunting, amotivation and loss of insight. Accompanying abnormalities often include additional behavioural features (e.g. mental rigidity and inflexibility, distraction and impersistence, perseverative and stereotyped behaviour, utilisation behaviour), speech and language disorder (e.g. echolalia, perseveration, mutism) and physical signs (primitive reflexes, incontinence, akinesia, rigidity and tremor). Dysexecutive features include, for example, lack of attention, poor planning, and impaired abstraction and problem solving (Elman et al., 2008). This constellation of symptoms tends to be caused by a bilateral, or right-sided, orbital and medial frontal lobe degeneration (Williams et al., 2005).

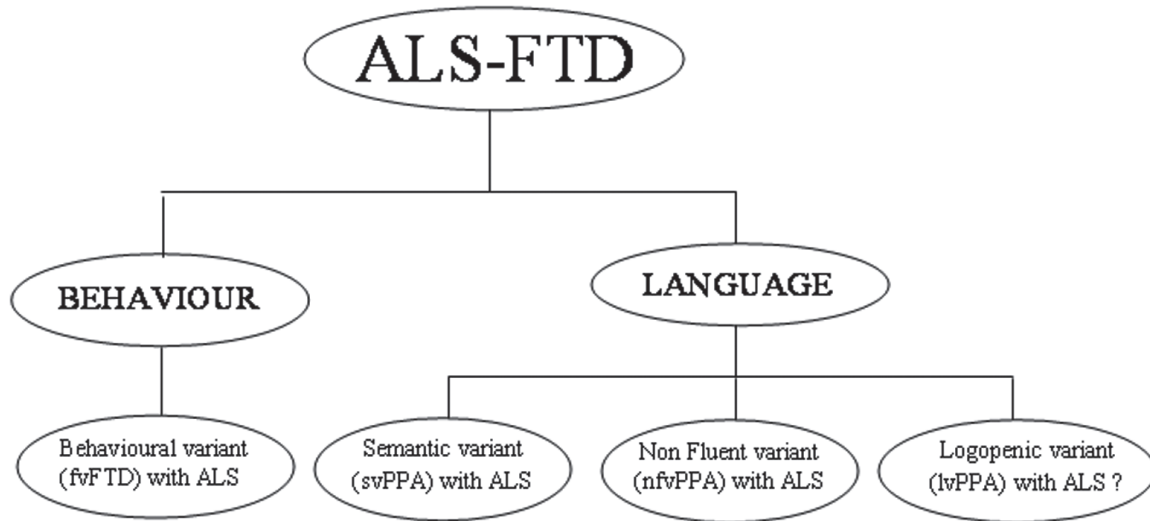


Fig. 2. - Classification of FTD clinical subforms potentially associated with ALS (adapted from Lillo and Hodges, 2009).

The clinical picture of nonfluent variant PPA (nfvPPA), also known as progressive nonfluent aphasia or PNFA, is characterised by prevalent expressive language breakdown, in which agrammatism, paraphasic errors, dysprosodia and anomia occur in the context of relatively preserved word comprehension in the early stages. Oral apraxia, impaired repetition, alexia and agraphia also may be present. This aphasic pattern is associated with a prevalent anterior peri-Sylvian atrophy in the left hemisphere due to atrophy of the insular and inferior frontal regions (Gorno-Tempini et al., 2004; 2011; Lillo and Hodges, 2009; Grossman, 2010). The salient manifestation of semantic variant PPA (svPPA), usually indicated as semantic dementia (SD), is a profound loss of conceptual knowledge that interferes with naming, object and face knowledge, comprehension and reading (Mesulam et al., 2009). Phonological and grammatical aspects of language, visuospatial skills, praxis and episodic memory are relatively preserved for a long time. This pattern is associated with bilateral, commonly asymmetric (left greater than right), atrophy of the anterior and ventral temporal cortex.

Finally, the logopenic variant PPA (lvPPA) is characterised by word retrieval in spontaneous speech and confrontation naming and deficits in sentence repetition. The language production deficit is distinct from

that of patients with the nfvPPA because there is no agrammatism, no distortions and no prosodic problems. The involvement of the left temporo-parietal junction area (i.e. posterior superior and middle temporal gyri and supramarginal and angular gyri) has been related to lvPPA (Gorno-Tempini et al., 2004). Predictably, some FTD patients have a mixed clinical picture of fvFTD, and PPA syndromes (Neary et al., 2005).

fvFTD, nfvPPA and svPPA have been described within the ALS population, although varied frequencies of FTD subtypes have been reported. Nevertheless, the discrepancies likely reflect biases introduced by small population-base studies, diverse diagnostic criteria, different cognitive measures used, different control for motor adjustment and subjectivity in behavioural assessment. Currently, there are no reported cases of lvPPA, the most recently and least studied PPA variant, in association with ALS.

Rakowicz et al. (1998), in an unselected population based cohort of patients, with ALS, estimated that 17% had clear dementia and 11% showed clear evidence of language impairment, whereas in tertiary care clinics, the prevalence of impairment fulfilling the criteria for clear dementia ranged from 15% (Ringholz et al., 2005) to 52% (Lomen-Hoerth et

al., 2003). Lomen-Hoerth et al. (2003) administered a detailed frontal lobe-neuropsychological testing in 44 ALS patients reporting that 12 had a fvFTD variant, 4 had a PNFA and 2 had SD. In contrast, another study carried out comprehensive neuropsychological evaluation of 279 ALS patients, found that 63% of patients who had ALS and dementia had a language variant of FTD, more consistent with PNFA or SD (Ringholz et al., 2005). Rippon and colleagues (2006) reported dementia in 23% of their ALS cohorts but used the *Diagnostic and Statistical Manual of Mental Disorders, Fourth Edition* (DSM-IV) criteria, which uses memory impairment as the meaning feature of dementia. Murphy et al. (2007) using Neary's criteria for the three subtypes of FTD examined 23 ALS patients: 5 met criteria for fvFTD; 2 had a SD; and 1 had PNFA.

Behavioural, cognitive, and linguistic symptoms may overlap, but aphasic symptoms can be an early and dominant feature for a long time in ALS, independently from dementia (Rakowicz and Hodges, 1998; Bak, 2010). A rapidly progressive aphasic dementia has been documented and proposed to represent a distinctive clinical entity (Caselli et al., 1993; Bak and Hodges, 2001; Catani et al., 2004). Bak et al. (2001) named "motor neuron disease-dementia-aphasia syndrome" this form. Alternatively, progressive non-fluent aphasia can be an early and prominent feature of ALS without dementia (Michaux et al., 1955; Caselli et al., 1993; Doran et al., 1995). There is considerable evidence of a selective deficit when processing verbs rather than nouns, both in production and in comprehension tasks, related to a loss of anterior regions of the language system (Bak et al., 2001; Bak and Hodges, 2004). Writing errors consisting of paraphasias such as substitutions, omissions, or syntactic errors have been reported both in demented and non demented ALS patients (Ferguson and Boller, 1977; Ferrer et al., 1991; Ichikawa et al., 2008; Tsuji-Akimoto et al., 2010). Dysgraphia was also reported in patients with a diagnosis of primary lateral sclerosis (Zago et al., 2008). Gainotti et al. (2008) studied a singular case of a 53-year-old right-handed woman with a prevalent right fronto-temporal degeneration and ALS who showed massive defects in recognition of familiar people and severe behavioural disorders.

With regard to behaviour, there are no published studies on the incidence and prevalence of the behav-

oural changes in ALS/FTD. However, single case reports showed that ALS/FTD patients exhibited both positive and negative symptoms and the spectrum of the abnormalities may be similar to those observed in FTD patients. ALS/FTD patients may present as socially disinhibited, with excessive sociability, unaware or unconcerned by disability (e.g. Fragnito, 1907; Ziegler, 1930; Vercelletto et al., 1995), or conversely lacking appropriate emotions, apathetic, inert, and emotionally blunted (e.g. Robertson, 1953; Corsino and Lugaesi, 1956; Cavalleri and De Renzi, 1994). These phenotypic variants indicate probable differences on the distribution of neural damage. In a recent study, Gibbons et al. (2008) examined 16 ALS patients in a specialized neurological motor neuron disease clinic. Behavioural changes, evaluated with the *Manchester FTD Behavioural Interview*, a semi-structured behavioural interview designed to explore abnormalities in FTD, revealed a range from behavioural stability consistent with premorbid functioning to profound frontally-mediated dysfunction. The most commonly reported behavioural change was an increase in self centredness and irritability, 69% and 61% of patients respectively. Other abnormalities included exaggerated displays of emotions (50%), blunting of emotions (25%), disinhibition and lack of insight (13%).

However, behaviour impairment in ALS/FTD patients remain an under-investigated area. For example disinhibition and sexual disturbances, which are features in FTD, are rarely reported in literature as a behavioural manifestation of ALS (Wolley and Katz, 2008; Anneser et al., 2008).

Some ALS-FTD patients with early high prevalence of psychotic features, such as hallucinations and delusions, has been reported (Pilcz, 1898; Nitri and Rosemberg, 1998; Lamer, 2008).

Generally in ALS-FTD, the clinical manifestations of FTD antedated the appearance of motor signs and the disease shows a more rapid and tumultuous course in comparison to the one observed in patients with FTD or ALS alone (Neary et al., 1990; Irwin et al., 2007).

Vercelletto et al. (1999) observed five sporadic cases of FTD which all preceded the appearance of typical ALS. The FTD rapidly became severe, within 12-18 months, and the delay between the presented onset of FTD symptomatology and ALS was short (12-26 months). Guedj et al. (2007) in a study of 24 patients

who had ALS/FTD observed that 58% experienced the onset of FTD more than 3 years before ALS, whereas 38% reported simultaneous onset. Murphy et al. (2007) in a prospective study of ALS patients found that those who met criteria for dementia, exhibited cognitive or behavioural decline on an average of 7 years and 7 months before motor symptoms. Some researchers hypothesize that patients who have ALS die before cognitive or behavioural impairments become apparent, in contrast to patients who develop FTD and have years to develop ALS (Olney et al., 2005; Wolley and Katz, 2008).

Some studies have reported that ALS patients with bulbar-onset may be at increased risk of developing dementia compared to limb-onset patients (Neary et al., 2000; Lomen-Hoerth et al., 2003; Schreiber et al., 2005). It was speculated that disruption to cortical pathways might be more widespread in bulbar patients because of the relatively large and close fronto-cortical representation area for bulbar structures (Schreiber et al., 2005). However, in some patients this special susceptibility of bulbar weakness for dementia has not been confirmed (Kew et al., 1993; Neary et al., 2000; Portet et al., 2001; Ringholdz et al., 2005; Elman et al., 2008; Raaphorst et al., 2010).

### Basic research evidence: neuroimaging and neuropathology

Also basic research investigations suggest the presence of a *continuum* between ALS and FTD. There is compelling evidence of similar pathological and biochemical alterations between ALS and FTD using neuroimaging tools and histochemical procedures.

#### *Neuroimaging in ALS with cognitive impairment*

A number of neuroimaging studies, both structural and functional, sustain the hypothesis of brain involvement beyond the motor regions in ALS (Kiernan and Hudson, 1994; Agosta et al., 2010). In general, research suggest a high correlation between the neuroimaging results and those of neuropsychological tests.

Serial CT and MRI studies in ALS patients with dementia showed a progressive atrophy in frontotemporal lobes and limbic areas (Kato et al., 1994).

Frontotemporal hypoperfusion (SPECT) and hypometabolism (PET) changes have been described in cognitively unimpaired patients with ALS, although the changes were greater in mild to moderate forms of ALS (Dalakas et al., 1987; Ohnishi et al., 1990; Ludolph et al., 1992; Kew et al., 1993; Talbot et al., 1995; Garraux et al., 1999; Lloyd et al., 2000; Abrahams et al., 2005; Guedj et al., 2007). Voxel-based morphometry (VBM) has identified mild whole-brain volume loss and frontotemporal atrophy in ALS patients consistent with the milder cognitive and social deficit observed in these patients (Mezzapesa et al., 2007). All these data further encourage the view of a *continuum* between ALS and FTD.

The metabolic and perfusional changes observed in the cerebral cortex of patients who have definite ALS-FTD, however, seem to be more congruent with those of patients with only FTD. VBM showed gray matter atrophy affecting prevalently the frontal and temporal lobes (Chang et al., 2005; Whitwell et al., 2006; Elman et al., 2008). Chang et al. (2005) indicate that volume reductions in patients who had ALS-FTD were greater, particularly in the left hemisphere, than in patients who had ALS and no dementia. However, Murphy et al. (2007) using MRI found that right temporal lobe volume loss was most predictive of classification in a frontotemporal dysfunction group (Murphy et al., 2007). Avants et al. (2009) used high-resolution diffeomorphic image normalization and serial MRI to provide the first assessment of longitudinal cortical atrophy in patients with FTD/ALS relative to controls. Significant effects occur in the premotor cortex, primary motor cortex, and parietal lobe bilaterally in Brodmann areas (BA) 4, 6, and 7. The average annual cortical atrophy over significant voxels in FTD/ALS on the right and left was 8.5% and 7.6%, respectively, in BA4; 8.1% and 5.9% in BA6; and 3.6% and 2.2% in BA7. For all cortices in FTD/ALS, the atrophy rate was 1.0% per year; in elderly controls, 0.25% per year. The local atrophy rate did not correlate with overall brain atrophy, nor did age and overall brain atrophy rates correlate.

#### *The molecular and neuropathological basis of ALS/FTD*

The classification of FTD (or FTLT when histopathological and molecular basis is considered), has been fraught with controversy due in large part

to substantial gaps in the understanding of the cellular and molecular neuropathological correlates of the clinical manifestations of FTDs. As the clinical manifestations of different FTD variants do not enable prediction of the neuropathological or genetic basis of the dementia in a given patient, it was recommended that the clinically diverse variants of FTD should be referred to collectively as FTD to emphasize the shared clinical features enabling differentiation from other dementias during life, but without making assumptions about their neuropathological correlates or underlying disease processes (McKhann et al., 2001).

More recent evidence on the convergence of the different clinical syndromes in both FTDs with tau pathology (i.e., tauopathies which account for ~45% of FTLN cases) or without associated tau pathology during the disease course supports this notion (Safa Al-Sarraj, 2008). Moreover, “ubiquitin only dementia” has been shown to account for ~50% of FTLN cases, and FTLN-U is distinguished from FTLN tauopathies (i.e. FTLN-Tau) by the presence of frontotemporal degeneration and ubiquitin-positive, but tau- and  $\alpha$ -synuclein-negative inclusions. Using ubiquitin and novel monoclonal antibodies generated from FTLN-U brains, at least four morphological subtypes of FTLN-U were identified based on the type and distribution of the ubiquitin-positive inclusions throughout the frontotemporal cortex and hippocampus.

In 2006, the notion that pathological ubiquitinated trans-activating responsive (tar) sequence DNA binding protein, TDP-43 (a 414 amino acid nuclear protein of 43KD), is involved in human disease was proposed when TDP-43 was discovered by Neumann et al. (2006) to be the major disease protein in FTLN-U (now known as FTLN-TDP), FTLN with MND (FTLN-MND) and ALS. This discovery had shed some light on these diseases, suggesting a common pathogenesis linked to TDP-43 abnormalities and providing a biological rationale for FTD in ALS (Arai et al., 2006; Elman et al., 2008; Mackenzie and Rademakers, 2008; Lillo and Hodges, 2009).

A classification scheme has been proposed in which pathological TDP-43 is the major disease defining pathology in the so-called primary TDP-43 proteinopathies, which mainly include ALS, FTLN-TDP and their transition forms, while a second

category of disorders includes neurodegenerative diseases wherein there is concomitant TDP-43 pathologies, and a third group comprises those neurodegenerative conditions with minor or no significant TDP-43 pathology (Geser et al., 2009). This scheme reflects the considerable overlap of clinicopathological features between all neurodegenerative diseases (Armstrong et al., 2005). More recently, detailed clinico-pathological studies on the whole spectrum of TDP-43-related neurodegeneration have become available, and have contributed to establishing the significance of pathological TDP-43 for ALS and FTLN-U (Geser et al., 2009).

The spectrum of TDP-43 pathology and the associated recommended neuropathological nomenclature, including the morphological subtypes, have been the subject of detailed reviews, with the conclusion that there is a significant overlap of both clinical and pathological features among the major TDP-43 proteinopathies (Sampathu et al., 2006; Mackenzie et al., 2009, 2010; Neumann et al., 2009). In fact, ALS, ALS-D/FTLN-MND and FTLN-U may be situated at different points along one continuous and broad clinicopathological spectrum of multisystem degenerations. Other than the defining clinical syndromes in pyramidal motor system and cognitive domains, extrapyramidal signs were the most common clinical features, consistent with the robust pathology found in the striatum and substantia nigra (Geser et al., 2009). FTLN-U subtype 1 (characterized by frequent long neuritic profiles predominantly in the superficial cortical layers) appears to represent the most “cortical variant of degeneration” in comparison with subtypes 2 (with neuronal cytoplasmic inclusions in superficial and deep cortical layers) and 3 (with abundance of small neuritic profiles and neuronal cytoplasmic inclusions predominantly in the superficial cortical layers). In terms of LMN pathology, the latter two subtypes (especially subtype 2) are closer to the MND phenotype when compared with subtype 1. Further, cases with predominantly neuronal intracytoplasmic inclusions (i.e., subtype 2) can present with clinical ALS in addition to FTD whereas cases with predominantly dystrophic neurites (i.e., subtype 1) tend to show the semantic variant of FTD, and when neuronal cytoplasmic inclusions and dystrophic neurites are coupled with neuronal intranuclear inclusions, albeit less frequent (i.e., subtype 3), fvFTD and PNFA is common with



or without clinical MND (MacKenzie et al., 2006). Notably, FTL-D-U patients with numerous neuronal cytoplasmic inclusions, as seen in subtypes 2 or 3, have shorter survival times than those with subtype 1 potentially indicating a link to the involvement of LMNs in decreased survival, as it was previously shown that FTL-D-ALS has significantly shorter survival than FTL-D-U (Josephs et al., 2005). It was also shown that inclusion formation is present to a greater extent than neuronal loss and gliosis in neocortex of ALS cases which may signify that TDP-43 pathology develops very early in the disease state and precedes overt neurodegeneration by some as yet unspecified period of time (Geser et al., 2009). However, in advanced disease stages, TDP-43 inclusion pathology and reactive tissue changes can be similarly abundant due to more profound degenerative changes.

Recent findings of mutations in the *TARDBP* gene, on chromosome 1p36, in cases of familial autosomal-dominant and rare sporadic ALS patients further corroborate the significance of pathological TDP-43 as being mechanistically implicated in the disease process (Sreedharan et al., 2008; Kabashi et al., 2008; Van Deerlin et al., 2008; Corrado et al., 2009). Although no mutations in the *TARDBP* gene have yet been reported in either familial or sporadic FTL-D-U, single patients with FTL-D-MND and *TARDBP* mutations do exist (Benajiba et al., 2009). Significantly, many of the *TARDBP* variants display autosomal-dominant inheritance in familial ALS patients, suggesting that they may be pathogenic mutations. Mutations in a gene encoding another DNA/RNA-binding protein with striking structural and functional similarities to TDP-43 called *FUS* (fused in sarcoma) or *TLS* (translocation in liposarcoma) have been recently reported to trigger degeneration of motor neurons (Kwiatkowski et al., 2009; Vance et al., 2009; Lagier-Tourenne and Cleveland, 2009) and be responsible of FTD (Ticozzi et al., 2009; 2011).

Further evidence for the overlap between ALS and FTD comes from well documented families in which various members show either ALS, FTD or both, in whom linkage has been related to chromosome 9 even if the causative gene mutation is yet to be identified (Valdmanis et al., 2007; Boxer et al., 2010).

## Evaluation of neuropsychological deficits in ALS patients

The formal diagnosis of cognitive and behavioural impairments in ALS would ideally be accomplished through detailed neuropsychological testing (Elman et al., 2008). Psychometric evaluation offers the unique opportunity to capture cognitive/behavioural deterioration in ALS in its mildest sub-clinical stages. Working guidelines for optimum neuropsychological assessment have been suggested by Strong et al. (2009). Due to the complexity of a formal assessment for an FTD syndrome in ALS, a hierarchical approach might be required. The evaluation could include preliminary screening (2-5 minutes), a brief assessment (5-20 minutes) and, if possible, a longer validated mental status examination. For this last purpose a series of standardized neuropsychological tests which characterize different areas of executive functioning, memory and learning, attention/concentration, language and visuospatial abilities, were proposed. Table III summarizes these tests.

However, a word of caution is needed regarding the use of traditional neuropsychological instruments for ALS patients. As pointed out by Phukan et al. (2007) standard testing can underestimate or exaggerate the presence of cognitive impairments of ALS patients, because of the adoption of insensitive rapid screening tools (e.g. Mini Mental State Examination, Addenbrooke's Cognitive Examination) or tests that are highly demanding in terms of speed of cognitive processing, peripheral motor reaction time, fine motor control, and speech production.

In fact, even with moderate motor impairment or dysarthria due to bulbar dysfunction, the assessment of the accompanying cognitive impairment in ALS is complicated.

Consequently, neuropsychologists when assessing ALS patients must adopt measures designed to minimize time responses, requiring minimal speech production and motor performances (Phukan et al., 2007; Stukovnik et al., 2010).

Other reversible confounding factors that mimic cognitive decline or interfere with detection of impaired cognition in ALS have been proposed. These include mood changes, anxiety, respiratory problems, sleep disturbances, nocturnal hypoventilation and high-dose pharmacological treatment (Iivanainen et al., 1985; Irwin et al., 2007; Phukan

| Table III. - Neuropsychological test for the evaluation of cognitive/behavioural impairment in ALS (modify from Strong et al., 2009). |                                                                                                                                                                                                                               |
|---------------------------------------------------------------------------------------------------------------------------------------|-------------------------------------------------------------------------------------------------------------------------------------------------------------------------------------------------------------------------------|
| Domain                                                                                                                                | Test                                                                                                                                                                                                                          |
| Executive measure                                                                                                                     | Wisconsin Card Sorting Test, Controlled Oral Word Association, FAS, D Words, Animal Fluency, Written Word Fluency, Design Fluency, California Card Sorting Test, Stroop Colour-Word Interference Test, Trail Making Test      |
| Memory/Learning                                                                                                                       | Rey Auditory Verbal Learning Test, California Verbal Learning Test II, Warrington Recognition Memory Test, Wechsler Logical Memory and Visual Reproduction, Wechsler Paired Associate Learning, Kendrick Object Learning Test |
| Attention/Concentration                                                                                                               | Verbal Serial Attention Test, Consonant Trigrams Test, Symbol Digit Modality Test, Paced Auditory Serial Addition Task, Digit Span                                                                                            |
| Language                                                                                                                              | Boston Naming Test, Graded Naming Test, Pyramid and palm Trees, Peabody Picture Vocabulary Test, British Picture Vocabulary Test,, Test for the Reception of Grammar                                                          |
| Visual/Spatial                                                                                                                        | Judgement of Line Orientation, Benton Facial Recognition Test, Block Design, Motor-Free Visual Perception Test-Revised, Visual Object and Space Perception Battery                                                            |
| Emotional/Behavioural functioning                                                                                                     | Neuropsychiatric Inventory, Frontal Behavioural Inventory, Frontal Systems Behavioural Scale                                                                                                                                  |

et al., 2007). Assessments must also include mood, anxiety and sleeping scales, evaluation of O2 levels and medication side effects. In patients with an FTD-like behavioural and cognitive syndrome, neuropsychological testing might be more useful when combined with carer-based instruments for measurement of behavioural clues.

It is generally accepted that lesions to frontal or striatal-frontal circuits induce a wide variety of deficits in different domains: cognition, behaviour, social interaction (Dubois et al., 2008). The main detectable cognitive and/or behavioural impairments in patients with ALS/FTD concern the executive functions and self-regulation, these both mirroring frontal lobe dysfunction. The term executive functions has been used to encompass the actions of analysis and selection of the information to be processed, holding the information in mind (working memory), planning of the behaviour response, inhibiting responses, strategy development and use, flexible sequencing of actions, maintenance of behavioural set, resistance to interference, retrieving information from memory, fluency and so forth. Executive functions can be roughly assessed by distinctive neuropsychological tests and batteries (Dubois et al., 2008; Strong et al., 2009). Several researchers have found consistent deficit in tests of verbal fluency in demented and non-demented ALS patients alike (Lomen-Hoerth et al., 2003; Abrahams et al., 2004). Letter fluency deficits in ALS patients have

been shown to be independent of motor disability or speech weakness using a written version which incorporates a motor control condition and correction for motor speed (Abrahams et al., 1997; 2000). The verbal fluency deficit has been interpreted as a disturbance of the supervisory attentional systems or the central executive component of working memory, which is regulated by the frontal lobes (Abrahams et al., 2000). Notably, fluency deficits are not limited to verbal abilities but also to non-verbal fluency (designs), supporting the notion of an underlying deficit of response generation (Abrahams et al., 2000; Neary et al., 2000).

Recently, ALS-FTD patients have been found to perform poorly on social cognition tasks such as interpretation of cartoons and stories in which it is necessary to interpret social situations and ascribe mental states to others (Gibbons et al., 2007).

Some standardized short instruments for the assessment of cognition in ALS has been recently proposed (Flaherty-Craig et al., 2006; Gordon et al., 2007).

In particular, Flaherty-Craig et al. (2006) developed a promising 20-minute screening evaluation to detect frontal dysfunction in patients with ALS that incorporated measures of verbal associative fluency, verbal abstract reasoning and judgement. Cognitive deficits were found in more than half of the non-bulbar ALS patients and two-thirds of the bulbar ALS patients.

Cognition has not been fully investigated in the late stages of the disease because of patients physical impairments, with the exception of the Lakerveld et al. (2008) study in which an adapted version of Neumann and Kotchoubey (2004) neuropsychological battery was applied. Even if characterized by a small sample size and a restricted number of tests applied this remains an interesting application of a possible testing response mode (yes/no answers only). More recently, new technologies such as eye-tracking (ET) or Brain Computer Interface (BCI) have been used to test cognition and frontal functions in ALS patients (Iversen et al., 2008; Poletti et al., 2009). In fact, ALS patients showed impairment in an antisaccade task suggesting frontal lobe dysfunctions. This evolving field could allow the neuropsychological testing of tracheostomized patients who could not perform traditional tests.

Frontal-lobe depending behavioural functions has been evaluated in ALS with rating scales such as Neuropsychiatry Inventory (Cummings et al., 1994), Frontal Behaviour Inventory (Kertesz et al., 2000) and Frontal Systems Behavioural Scale (Stout et al., 2003). The evaluation of behavioural abnormalities also suffers from other limitations compared with the assessment of cognitive disorders. Methodological biases are present in the detection and quantification of behaviour symptoms because they are not based on direct patients observation but mostly rely on caregivers' reports. The influence that caregivers' variables may have on symptom description and quantification is not always adequately taken into account (Silveri, 2007).

### Implication of cognitive and behavioural impairment on the management of ALS patients

The presence of ALS/FTD syndrome has relevant consequences for management of patients. Cognitive/behavioural loss with lack of awareness may reduce or impede the patient's ability to make complex end-of-life decisions or significant judgments about the welfare of their loved ones and their own interest. The decisions are broad in scope, and may include medical decisions such as percutaneous endoscopic gastrostomy (PEG), non-invasive positive pressure ventilation, mechanical ventilation, but

also financial and legal issues, including the validity of living wills and inheritances.

It is important to counsel patients early in the disease process to make decisions about finances and medical care to avoid problems if mental decline symptoms are evident to caregivers or physicians. Caregiver burden and stress for carers of ALS/FTD patients is very great and can lead to more problems than that associated with motor disability alone.

Survival is significantly shorter among patients with ALS-FTD than with classic ALS and this argues strongly that the issue does not represent a sub-clinical phenomenon that has little clinical relevance (Olney et al., 2005). Furthermore, patients with ALS-FTD are twice as likely to be noncompliant.

### Summary

Recently there has been a great upsurge in interest about the association of ALS with FTD. The interest has been stimulated by a variety of overlapping factors, including new biological discoveries related to the role of molecular and genetic findings (e.g. the role of TDP-43 and *FUS/TLS* in both disease).

The diagnosis of ALS-FTD is multidisciplinary with the demonstration, neuropsychologically, of a pervasive behavioural and frontal executive disturbance, neuradiologically of an overt focal frontotemporal degeneration and prospectively with the analysis of specific shared molecular, genetical and neuropathological patterns.

As a further biological support, we have recently found evidence of a genetic association of two single nucleotide polymorphisms on chromosome 9 with sporadic ALS, in line with findings from previous independent genome-wide association studies (GWAs) of ALS and linkage studies of ALS-FTD. This evidence together with earlier findings advocates that genetic variation at this locus on chromosome 9 causes sporadic ALS and familial ALS-FTD, further suggesting the clinico-biological overlap (Shatunov et al., 2010).

All these aspects need further characterization and refinements in order to provide new insights into the understanding of the defining characteristics of ALS-FTD. This could have important implications not only for academic research but relevant clinical implications for the management of ALS-FTD patients.

### Acknowledgements

The authors are deeply grateful to the patients and their caregivers. The authors also wish to extend their gratitude to Mrs. Palma Giannini who highly desired and inspired the ALS Meeting at IRCCS Neuromed on October 23, 2009.

### References

- Abrahams S., Goldstein L.H., Al-Chalabi A., Pickering A., Morris R.G., Passingham R.E., Brooks D.J., Leigh P.N. Relation between cognitive dysfunction and pseudobulbar palsy in amyotrophic lateral sclerosis. *J. Neurol. Neurosurg. Psychiatry*, **62**: 464-472, 1997.
- Abrahams S., Leigh P.N., Harvey A., Vythelingum G.N., Gris e D., Goldstein L.H. Verbal fluency and executive dysfunction in amyotrophic lateral sclerosis (ALS). *Neuropsychologia*, **38**: 734-747, 2000.
- Abrahams S., Goldstein L.H., Simmons A., Brammer M., Williams S.C., Giampietro V., Leigh P.N. Word retrieval in amyotrophic lateral sclerosis: a functional magnetic resonance imaging study. *Brain*, **127**: 1507-1517, 2004.
- Abrahams S., Leigh P.N., Goldstein L.H. Cognitive change in ALS: a prospective study. *Neurology*, **64**:1222-1226, 2005.
- Agosta F., Chi o A., Cosottini M., De Stefano N., Falini A., Mascalchi M., Rocca M.A., Silani V., Tedeschi G., Filippi M. The Present and the Future of Neuroimaging in Amyotrophic Lateral Sclerosis. *Am. J. Neuroradiol.*, **31**: 1769-1777, 2010.
- Anneser J.H.H., Fox R.J., Borasio G.D. Inappropriate sexual behavioural in a case of ALS and FTD: successful treatment with Sertraline. *Amyotroph. Lateral Scler.*, **8**: 189-190, 2008.
- Arai T., Hasegawa M., Akiyama H., Ikeda K., Nonaka T., Mori H., Mann D., Tsuchiya K., Yoshida M., Hashizume Y., Oda T. TDP-43 is a component of ubiquitin-positive tau-negative inclusions in frontotemporal lobar degeneration and amyotrophic lateral sclerosis. *Biochem. Biophys. Res. Commun.*, **351**: 602-611, 2006.
- Armstrong R.A., Lantos P.L., Cairns N.J. Overlap between neurodegenerative disorders. *Neuropathology*, **25**: 111-124, 2005.
- Avants B., Khan A., McCluskey L. Elman, L. and Grossman M. Longitudinal cortical atrophy in amyotrophic lateral sclerosis with frontotemporal dementia. *Arch. Neurol.*, **66**: 138-139, 2009.
- Bak T.H. and Hodges J.R. Motor neurone disease, dementia and aphasia: coincidence, co-occurrence or continuum? *J. Neurol.*, **248**: 260-270, Review, 2001.
- Bak T.H., O'Donovan D., Xuereb J.H., Boniface S., Hodges J.R. Selective impairment of verb processing associated with pathological changes in Brodmann areas 44 and 45 in the motor neurone disease-dementia-aphasia syndrome. *Brain*, **124**: 103-120, 2001.
- Bak T.H. and Hodges J.R. The effects of motor neurone disease on language: further evidence. *Brain and Language*, **89**: 354-361, 2004.
- Bak T.H. Motor neuron disease and frontotemporal dementia: One, two, or three disease. *Ann. Indian. Acad. Neurol.*, **13**: 31-38, 2010.
- Benajiba L., Le Ber I., Camuzat A., Lacoste M., Thomas-Anterion C., Couratier P., Legallic S., Salachas F., Hannequin D., Decousus M., Lacomblez L., Guedj E., Golfier V., Camu W., Dubois B., Campion D., Meininger V., Brice A. French Clinical and Genetic Research Network on Frontotemporal Lobar Degeneration/ Frontotemporal Lobar Degeneration with Motoneuron Disease. TARDBP mutations in motoneuron disease with frontotemporal lobar degeneration. *Ann. Neurol.*, **65**: 470-473, 2009.
- Boccardi M., Sabatoli F., Laasko M.P., Testa M., Rossi R., Beltramello A., Soininen H., Frisoni G.B. Frontotemporal dementia as a neural system disease. *Neurobiol. Aging*, **26**: 37-44, 2005.
- Boxer A.L., Mackenzie I.R., Boeve B.F., Baker M., Seeley W.W., Crook R., Feldman H., Hsiung G.Y., Rutherford N., Laluz V., Whitwell J., Foti D., McDade E., Molano J., Karydas A., Wojtas A., Goldman J., Mirsky J., Sengdy P., Dearmond S., Miller B.L., Rademakers R. Clinical, neuroimaging and neuropathological features of a new chromosome 9p-linked FTD-ALS family. *J. Neurol. Neurosurg. Psychiatry*, **82**: 196-203, 2011.
- Brooks B.R. El Escorial Wordl Federation of Neurology criteria for the diagnosis of amyotrophic lateral sclerosis. Subcommittee on Motor Neuron Disease/Amyotrophic Lateral Sclerosis of the Wordl Federation of Neurology Research Group on Neuromuscular Disease and the El Escorial 'Clinical limits of amyotrophic lateral sclerosis' workshop contributors. *J. Neurol. Sci.*, **124** (Suppl.): 96-107, 1994.
- Brooks B.R., Miller R.G., Swash M. Munsat T.L. Wordl Federation of Neurology Research Group

- on Motor Neuron Diseases: El Escorial revisited: revised criteria for the diagnosis of amyotrophic lateral sclerosis. *Amyotroph. Lateral Scler. Other Motor Neuron Disord.*, **1**: 293-239, 2000.
- Caselli R.J., Windebank A.J., Petersen R.C., Komori T., Parisi J.E., Okazaki H., Kokmen E., Iverson R., Dinapoli R.P., Graff-Radford N.R., et al. Rapidly progressive aphasic dementia and motor neuron disease. *Ann. Neurol.*, **33**: 200-207, 1993.
- Catani M., Piccirilli M., Geloso M.C., Cherubini A., Finali G., Pelliccioli G., Senin U., Mecocci, P. Rapidly Progressive Aphasic Dementia with motor neuron disease: a distinctive clinical entity. *Dement. Geriatr. Cogn. Disord.*, **17**: 21-28, 2004.
- Cavalleri F. and De Renzi E. Amyotrophic lateral sclerosis with dementia. *Acta Neurol. Scand.*, **89**: 391-394, 1994.
- Chang J.L., Lomen-Hoerth C., Murphy J., Henry R.G., Kramer J.H., Miller B.L., Gorno-Tempini M.L. A voxel-based morphometry study of patterns of brain atrophy in ALS and ALS/FTLD. *Neurology*, **65**: 75-80, 2005.
- Corrado L., Ratti A., Gellera C., Buratti E., Castellotti B., Carlomagno Y., Ticozzi N., Mazzini L., Testa L., Taroni F., Baralle F.E., Silani V., D'Alfonso S. High frequency of TARDBP gene mutations in Italian patients with amyotrophic lateral sclerosis. *Hum. Mutat.*, **30**: 688-694, 2009.
- Corsino G.M. and Lugaresi E. Sclerosi laterale amiotrofica e turbe psichiche. *Riv. Sper. Freniatr. Med. Leg.*, **80**: 870-876, 1956.
- Culler A. Troubles mentales dans la sclérose latérale amyotrophique. *Archives de Neurologie*, **21**: 433-450, 1906.
- Cummings J.L., Mega M., Gray K., Rosenberg-Thompson S., Carusi D.A., Gornbein J. The Neuropsychiatric Inventory: comprehensive assessment of psychopathology in dementia. *Neurology*, **44**: 2308-2314, 1994.
- Dalakas M.C., Hatazawa J., Brooks R.A., Di Chiro G. Lowered cerebral glucose utilization in amyotrophic lateral sclerosis. *Ann. Neurol.*, **22**: 580-586, 1987.
- De Caro D. Un caso di sclerosi laterale amiotrofica con demenza. Contributo allo studio delle lesioni corticali nella malattia di Charcot. *Rass. Studi Psichiatr.*, **30**: 705-722, 1941.
- Delay J., Brion S., Escourolle R., Marty R. Sclérose latérale amyotrophique et démence (a propos de deux cas anatomo-cliniques). *Rev. Neurol.*, **100**: 191-204, 1959.
- Doran M., Xuereb J., Hodges J.R. Rapidly progressive aphasia with bulbar motor neuron disease: a clinical and neuropsychological study. *Behav. Neurol.*, **8**: 169-180, 1995.
- Dubois B and Andrade K. Executive dysfunction and neuropsychological testing. In: Duyckarten C., Litvan I. (Eds.) *Dementia (Handbook of Clinical Neurology Vol. 89) (3rd series)*. Elsevier B.V., 2008.
- Elman L.B., McCluskey L. Grossman M. Motor neuron disease and frontotemporal lobar degeneration: a tale of two disorders linked to TDP-43. *Neurosignals*, **16**: 85-90, 2008.
- Ferguson J.H. and Boller F. A different form of agraphia: syntactic writing errors in patients with motor speech and movement disorders. *Brain Lang.*, **4**: 382-389, 1977.
- Ferrer I., Roig C., Espino A., Peiro G., Matias Guiu X. Dementia of frontal lobe type and motor neuron disease. A Golgi study of the frontal cortex. *J. Neurol. Neurosurg. Psychiatry*, **54**: 932-934, 1991.
- Flaherty-Craig C., Eslinger P., Stephens B., et al. A rapid screening battery to identify frontal dysfunction in patients with ALS. *Neurology*, **67**: 2070-2072, 2006.
- Fragnito O. I disturbi psichici nella sclerosi laterale amiotrofica. *Annali di Neurologia*, **25**: 273-287, 1907.
- Gainotti G., Ferraccioli M., Quaranta D., Marra C. Cross-modal recognition disorders for persons and other unique entities in a patient with right frontotemporal degeneration. *Cortex*, **44**: 238-248, 2008.
- Garraux G, Salmon E., Degueldre C., Lemaire C., Franck G. Medial temporal lobe metabolic impairment in dementia associated with motor neuron disease. *Neuroimage*, **10**: 149-162, 1999.
- Gentile F. I disturbi psichici nella sclerosi laterale amiotrofica. *Annali della Clinica delle Malattie Mentali e Nervose della R. Università di Palermo*, **3**: 330-349, 1909.
- Geser F., Martinez-Lage M., Kwong L.K., Lee V.M., Trojanowski J.Q. Amyotrophic lateral sclerosis, frontotemporal dementia and beyond: the TDP-43 diseases. *J. Neurol.*, **256**: 1205-1214, 2009.
- Gibbons Z.C., Snowden J.S., Thompson J.C., Happé F., Richardson A. Neary D. Inferring thought and action in motor neurone disease. *Neuropsychologia*, **45**: 1196-1207, 2007.
- Gibbons Z.C., Richardson A., Neary D., Snowden J.S. Behaviour in amyotrophic lateral sclerosis. *Amyotroph. Lateral Scler.*, **9**: 67-74, 2008.

- Gordon PH, Wang Y, Doorish C, Lewis M, Battista V, Mitsumoto H, Marder K. A screening assessment of cognitive impairment in patients with ALS. *Amyotroph. Lateral. Scler.*, **8**: 362-5, 2007.
- Gorno-Tempini M.L., Dronkers N.F., Rankin K.P., Ogar J.M., Phengrasamy L., Rosen H.J., Johnson J.K., Weiner M.W., Miller B.L. Cognition and anatomy in three variants of primary progressive aphasia. *Ann. Neurol.*, **55**: 335-346, 2004.
- Gorno-Tempini M.L., Hillis A.E., Weintraub S., Kertesz A., Mendez M., Cappa S.F., Ogar J.M., Rohrer J.D., Black S., Boeve B.F., Manes F., Dronkers N.F., Vandenberghe R., Rascovsky K., Patterson K., Miller B.L., Knopman D.S., Hodges J.R., Mesulam M.M., Grossman M. Classification of primary progressive aphasia and its variants. *Neurology*, **76**: 1006-1014, 2011.
- Gozzano M. Sulla istopatologia e la patogenesi della sclerosi laterale amiotrofica. *Riv. Neurol.*, **5**: 165-216, 1936.
- Grossman M. Primary progressive aphasia: clinicopathological correlations. *Nat. Rev. Neurol.*, **6**: 88-97, 2010.
- Guedj E., Le Ber I., Lacomblez L., Dubois B., Verpillat P., Didic M., Salachas F., Vera P., Hannequin D., Lotterie J.A., Puel M., Decousus M., Thomas-Antérion C., Magne C., Vercelletto M., Bernard A.M., Golfier V., Pasquier J., Michel B.F., Namer I., Sellal F., Bochet J., Volteau M., Brice A., Meininger V., French Research Network on FTD/FTD-MND, Habert M.O. Brain spect perfusion of frontotemporal dementia associated with motor neuron disease. *Neurology*, **69**: 488-490, 2007.
- Hodges J.R. and Miller B. The neuropsychology of frontal variant frontotemporal dementia and semantic dementia. Introduction to the special topic papers: Part II. *Neurocase*, **7**: 113-121, 2001.
- Hodges J.R., Davies R.R., Xuereb J.H., Casey B., Broe M., Bak T.H., Kril J.J., Halliday G.M. Clinicopathological correlates in frontotemporal dementia. *Ann. Neurol.*, **56**: 399-406, 2004.
- Ichikawa H., Koyama S., Ohno H., Ishihara K., Nagumo K., Kawamura M. Writing errors and anosognosia in amyotrophic lateral sclerosis with dementia. *Behav. Neurol.*, **19**: 107-116, 2008.
- Iivanainen M., Laaksonen R., Niemi M.L., Färkkilä M., Bergström L., Mattson K., Niiranen A., Cantell K. Memory and psychomotor impairment following high-dose interferon treatment in amyotrophic lateral sclerosis. *Acta Neurol. Scand.*, **72**: 475-480, 1985.
- Irwin D., Lipka C.F., Swearer J.M. Cognition and amyotrophic lateral sclerosis (ALS). *Am. J. Alzheimers Dis. Other Demen.*, **22**: 300-312, 2007.
- Iversen I.H., Ghanayim N., Kübler A., Neumann N., Birbaumer N., Kaiser J. A brain-computer interface tool to assess cognitive functions in completely paralyzed patients with amyotrophic lateral sclerosis. *Clin. Neurophysiol.*, **119**: 2214-2223, 2008.
- Jackson M., Lennox G., Lowe J. Motor neurone disease-inclusion dementia. *Neurodegeneration*, **5**: 339-350, 1996.
- Josephs K.A., Knopman D.S., Whitwell J.L., Boeve B.F., Parisi J.E., Petersen R.C., Dickson D.W. Survival in two variants of tau-negative frontotemporal lobar degeneration: FTL-D-U vs FTL-D-MND. *Neurology*, **65**: 645-647, 2005.
- Kabashi E., Valdmanis P.N., Dion P., Spiegelman D., McConkey B.J., Vande Velde C., Bouchard J.P., Lacomblez L., Pochigaeva K., Salachas F., Pradat P.F., Camu W., Meininger V., Dupre N., Rouleau G.A. TARDBP mutations in individuals with sporadic and familial amyotrophic lateral sclerosis. *Nat. Genet.*, **40**: 572-574, 2008.
- Kato S., Oda M., Hayashi H., Kawata A., Shimizu T. Participation of the limbic system and its associated areas in the dementia of amyotrophic lateral sclerosis. *J. Neurol. Sci.*, **126**: 62-69, 1994.
- Kertesz A., Nadkarni N., Davidson W., Thomas A.W. The Frontal Behavioral Inventory in the differential diagnosis of frontotemporal dementia. *J. Int. Neuropsychol. Soc.*, **6**: 460-468, 2000.
- Kew J.J.M., Goldstein L.H., Leigh P.N., Abrahams S., Cogrove N., Passingham R.E., Frackowiak R.S.J., Brooks D.J. The relationship between abnormalities of cognitive function and cerebral activation in amyotrophic lateral sclerosis: A neurocognitive and positron emission tomography study. *Brain*, **116**: 1399-1423, 1993.
- Kiernan J.A. and Hudson A.J. Frontal lobe atrophy in motor neuron diseases. *Brain*, **117**: 747-757, 1994.
- Kilani M., Micallef J., Soubrouillard C., Rey-Lardiller D., Demattei C., Dib M., Philippot P., Ceccaldi M., Pouget J., Blin O. A longitudinal study of the evolution of cognitive function and affective state in patients with amyotrophic lateral sclerosis. *Amyotroph. Lateral Scler. Other Motor Neuron Disord.*, **5**: 46-54, 2004.
- Kwiatkowski T.J. Jr, Bosco D.A., Leclerc A.L., Tamrazian E., Vanderburg C.R., Russ C., Davis A., Gilchrist J., Kasarskis E.J., Munsat T., Valdmanis P., Rouleau G.A., Hosler B.A., Cortelli P., de Jong

- P.J., Yoshinaga Y., Haines J.L., Pericak-Vance M.A., Yan J., Ticozzi N., Siddique T., McKenna-Yasek D., Sapp P.C., Horvitz H.R., Landers J.E., Brown R.H. Jr. Mutations in the FUS/TLS gene on chromosome 16 cause familial amyotrophic lateral sclerosis. *Science*, **323**: 1205-1208, 2009.
- Lagier-Tourenne C. and Cleveland D.W. Rethinking ALS: the FUS about TDP-43. *Cell*, **136**: 1001-1004, 2009.
- Lakerveld J, Kotchoubey B, Kübler A. Cognitive function in patients with late stage amyotrophic lateral sclerosis. *J. Neurol. Neurosurg. Psychiatry*, **79** (1): 25-29, 2008.
- Lamer A.J. Delusion of pregnancy in frontotemporal lobar degeneration with motor neurone disease (FTDL/MND). *Behav. Neurol.*, **19**: 199-200, 2008.
- Lillo P. and Hodges J.R. Frontotemporal dementia and motor neurone disease: Overlapping clinic-pathological disorders. *J. Clin. Neurosci.*, **16**: 1131-1135, 2009.
- Lloyd C.M., Richardson M.P., Brooks D.J., Al-Chalabi A., Leigh P.N. Extramotor involvement in ALS: PET studies with the GABA(A) ligand [(11)C] flumazenil. *Brain*, **123**: 2289-2296, 2000.
- Lomen-Hoerth C., Anderson T., Miller B. The overlap of amyotrophic lateral sclerosis and frontotemporal dementia. *Neurology*, **59**: 1077-1079, 2002.
- Lomen-Hoerth C., Murphy J., Langmore S., Kramer J.H., Olney R.K., Miller B. Are amyotrophic lateral sclerosis patients cognitively normal? *Neurology*, **60**: 1094-1097, 2003.
- Ludolph A.C., Langer K.J., Regard M. Herzog H., Kemper B., Kuwert T., Böttger I.G., Feinendegen L. Frontal lobe function in amyotrophic lateral sclerosis: a neuropsychologic and positron emission tomography study. *Acta Neurol. Scand.*, **85**: 81-89, 1992.
- Mackenzie I.R., Baborie A., Pickering-Brown S., Du Plessis D., Jaros E., Perry R.H., Neary D., Snowden J.S., Mann D.M. Heterogeneity of ubiquitin pathology in frontotemporal lobar degeneration: classification and relation to clinical phenotype. *Acta Neuropathol.*, **112**: 539-549, 2006.
- Mackenzie I.R. and Rademakers R. The role of TDP-43 in amyotrophic lateral sclerosis and frontotemporal dementia. *Curr. Opin. Neurol.*, **21**: 693-700, 2008.
- Mackenzie I.R., Neumann M., Bigio E.H., Cairns N.J., Alafuzoff I., Kril J., Kovacs G.G., Ghetti B., Halliday G., Holm I.E., Ince P.G., Kamphorst W., Revesz T., Rozemuller A.J., Kumar-Singh S., Akiyama H., Baborie A., Spina S., Dickson D.W., Trojanowski J.Q., Mann D.M. Nomenclature for neuropathologic subtypes of frontotemporal lobar degeneration: consensus recommendations. *Acta Neuropathol.*, **117**: 15-18, 2009.
- Mackenzie I.R., Neumann M., Bigio E.H., Cairns N.J., Alafuzoff I., Kril J., Kovacs G.G., Ghetti B., Halliday G., Holm I.E., Ince P.G., Kamphorst W., Revesz T., Rozemuller A.J., Kumar-Singh S., Akiyama H., Baborie A., Spina S., Dickson D.W., Trojanowski J.Q., Mann D.M. Nomenclature and nosology for neuropathologic subtypes of frontotemporal lobar degeneration: an update. *Acta Neuropathol.*, **119**: 1-4, 2010.
- Marie P. *Leçons sur le maladies de la moelle*. Paris, Masson & Cie, 1892.
- Massman P.J., Sims J., Cooke N., Haverkamp L.J., Appel V., Appel S.H. Prevalence and correlates of neuropsychological deficits in amyotrophic lateral sclerosis. *J. Neurol. Neurosurg. Psychiatry*, **61**: 450-455, 1996.
- McKhann G.M., Albert M.S., Grossman M., Miller B., Dickson D., Trojanowski J.Q.; Work Group on Frontotemporal Dementia and Pick's Disease. Clinical and pathological diagnosis of frontotemporal dementia: report of the Work Group on Frontotemporal Dementia and Pick's Disease. *Arch. Neurol.*, **58**: 1803-1809, 2001.
- Mesulam M., Rogalski E., Wieneke C., Cobia D., Rademaker A., Thompson C., Weintraub S. Neurology of anomia in the semantic variant of primary progressive aphasia. *Brain.*, **132**: 2553-2565, 2009.
- Mezzapesa D.M., Ceccarelli A., Dicuonzo F., Carella A., De Caro M.F., Lopez M., Samarelli V., Livrea P., Simone I.L. Whole-Brain and regional brain atrophy in amyotrophic lateral sclerosis. *Am. J. Neuroradiol.*, **28**: 255-259, 2007.
- Michaux L., Samson M., Harl J-M., Gruener J. Évolution démentielle de deux cas de sclérose latérale amyotrophique accompagnée d'aphasie. *Rev. Neurol.*, **92**: 357-367, 1955.
- Moretti R., Torre P., Antonello R.M., Carraro N., Cazzato G., Bava A. Complex cognitive disruption in motor neuron disease. *Dement. Geriatr. Cogn. Disord.*, **14**: 141-150, 2002.
- Murphy J.M., Roland G.H., Langmore S., Kramer J.H., Miller B.L., Lomen-Hoerth C. Continuum of frontal lobe impairment in amyotrophic lateral sclerosis. *Arch. Neurol.*, **64**: 530-534, 2007.
- Neary D., Snowden J.S., Gustafson L., Passant U., Stuss D., Black S., Freedman M., Kertesz A., Robert P.H., Albert M., Boone K., Miller B.L.,

- Cummings J., Benson D.F. Frontotemporal lobar degeneration. A consensus on clinical diagnostic criteria. *Neurology*, **51**: 1546-1554, 1998.
- Neary D., Snowden J.S., Mann D.M., Northen B., Goulding P.J., Macdermott N. Frontal lobe dementia and motor neuron disease. *J. Neurol. Neurosurg. Psychiatry*, **53**: 23-32, 1990.
- Neary D., Snowden J.S., Mann D.M. Cognitive change in motor neurone disease/amyotrophic lateral sclerosis (MND/ALS). *Neurol. Sci.*, **180**: 15-20, 2000.
- Neary D., Snowden J., and Mann D. Frontotemporal dementia. *Lancet Neurology*, **4**: 771-780, 2005.
- Neumann M., Sampathu D.M., Kwong L.K., Truax A.C., Micsenyi M.C., Chou T.T., Bruce J., Schuck T., Grossman M., Clark C.M., McCluskey L.F., Miller B.L., Masliah E., Mackenzie I.R., Feldman H., Feiden W., Kretschmar H.A., Trojanowski J.Q., Lee V.M. Ubiquitinated TDP-43 in frontotemporal lobar degeneration and amyotrophic lateral sclerosis. *Science*, **314**: 130-133, 2006.
- Neumann M., Kwong L.K., Lee E.B., Kremmer E., Flatley A., Xu Y., Forman M.S., Troost D., Kretschmar H.A., Trojanowski J.Q., Lee V.M. Phosphorylation of S409/410 of TDP-43 is a consistent feature in all sporadic and familial forms of TDP-43 proteinopathies. *Acta Neuropathol.*, **117**: 137-149, 2009.
- Neumann N. and Kotchoubey B. Assessment of cognitive functions in severely paralysed and severely brain-damaged patients: neuropsychological and electrophysiological methods. *Brain Res Brain Res Protoc.*, **14** (1): 25-36, 2004.
- Nitrini R. and Rosemberg S. Psychotic symptoms in dementia associated with motor neuron disease: a pathophysiological hypothesis. *J. Neuropsychiatry Clin. Neurosci.*, **10**: 456-458, 1998.
- Ohnishi T., Hoshi H., Jinnouchi S., Nagamachi S., Watanabe K., Mituyama Y. The utility of cerebral blood flow imaging in patients with the unique syndrome of progressive dementia with motor neuron disease. *J. Nucl. Med.*, **31**: 688-691, 1990.
- Olney R.K., Murphy J., Forsheve D., Garwood E., Miller B.L., Langmore S., Kohn M.A., Lomen-Hoerth C. The effects of executive and behavioural dysfunction on the course of ALS. *Neurology*, **65**: 1774-1777, 2005.
- Phukan J., Pender N., Hardiman O. Cognitive impairment in amyotrophic lateral sclerosis. *Lancet Neurology*, **6**: 994-1003, 2007.
- Pilcz A. Über ein Fall von amyotrophische laterale Sklerose und Paranoia. *Jahrbuch für Psychologie und Neurologie*, **17**: 221-222, 1898.
- Poletti B., Maringelli F., Lafronza A., Lombardi C., Meriggi P., Silani V. Anti-saccade paradigm in the cognitive frontal assessment of Amyotrophic Lateral Sclerosis. *Amyotroph. Lateral Scler. other Motor. Neuron Disord.*, **10** (Suppl 1): 45, 2009.
- Portet F., Cadilhac C., Touchon J., Camu W. Cognitive impairment in motor neuron disease with bulbar onset. *Amyotroph. Lateral Scler. Other Motor Neuron Disord.*, **2**: 23-29, 2001.
- Raaphorst J., de Visser M., Linszen W.H., de Haan R.J., Schmand B. The cognitive profile of amyotrophic lateral sclerosis: A meta-analysis. *Amyotroph. Latreral Scler.*, **11**: 27-37, 2010.
- Rakowicz W.P. and Hodges J.R. Dementia and aphasia in motor neuron disease: an underrecognised association? *Neurol. Neurosurg. Psychiatry*, **65**: 881-889, 1998.
- Resegotti E. Un caso di sclerosi laterale amiotrofica osservato nella clinica neuropatologica di Pavia. *Il Morgagni*, **49**: 301-316, 1907.
- Ringholz G.M., Appel S.H., Bradshaw M., Cooke N.A., Mosnik D.M., Schulz P.E. Prevalence and patterns of cognitive impairment in sporadic ALS. *Neurology*, **65**: 586-590, 2005.
- Rippon G.A., Scarmeas N., Gordon P.H. Murphy P.L., Albert S.M., Mitsumoto H., Marder K., Rowland L.P., Stern Y. An observational study of cognitive impairment in amyotrophic lateral sclerosis. *Arch. Neurol.*, **63**: 345-352, 2006.
- Robertson E. Progressive bulbar analysis hereditary incidence and intellectual impairment. *Arch. Neurol. Psychiatry*, **69**: 197-207, 1953.
- Robinson K.M., Lacey S.C., Grugan P., Glosser G., Grossman M., McCluskey L.F. Cognitive functioning in sporadic amyotrophic lateral sclerosis: a six month longitudinal study. *J. Neurol. Neurosurg. Psychiatry*, **77**: 668-670, 2006.
- Safa Al-Sarraj. Dementia and motor neuron disease. In: Duyckarten C., Litvan I. (Eds.) *Dementia (Handbook of Clinical Neurology Vol. 89) (3rd series)*. Elsevier B.V., 2008.
- Sampathu D.M., Neumann M., Kwong L.K., Chou T.T., Micsenyi M., Truax A., Bruce J., Grossman M., Trojanowski J.Q., Lee V.M. Pathological heterogeneity of frontotemporal lobar degeneration with ubiquitin-positive inclusions delineated by ubiquitin immunohistochemistry and novel monoclonal antibodies. *Am. J. Pathol.*, **169**: 1343-1352, 2006.



- Schreiber H., Gaigalat T., Wiedemuth-Catrinescu U., Graf M., Uttner I., Mucbe R., Ludolph A.C. Cognitive function in bulbar- and spinal-onset amyotrophic lateral sclerosis. A longitudinal study in 52 patients. *J. Neurol.*, **252**: 772-781, 2005.
- Shatunov A., Mok K., Newhouse S., Weale M.E., Smith B., Vance C., Johnson L., Veldink J.H., Van Es M., Van Den Berg L., Robberecht W., van Damme P., Hardiman O., Farmer A.E., Lewis C.M., Butler W.-L., Abel O., Andersen P.M., Fogh I., Silani V., Chiò A., Traynor B.J., Melki J., Meininger V., Landers J.E., McGuffin P.D., Glass J.D., Pall H., Leigh P.N., Hardy J., Brown, R.H.Jr, Powell J.F., Orrell R., Morrison K.E., Shaw P.J., Shaw C.E., Al-Chalabi A. Chromosome 9p21.2 in sporadic amyotrophic lateral sclerosis in the UK and seven other countries: a genome-wide association study. *Lancet Neurol*, **10**: 986-994, 2010.
- Silveri M.C. Frontotemporal dementia to Alzheimer's disease. *Dialogues Clin. Neurosci.*, **9**: 153-160, 2007.
- Sreedharan J., Blair I.P., Tripathi V.B., Hu X., Vance C., Rogelj B., Ackerley S., Durnall J.C., Williams K.L., Buratti E., Baralle F., de Bellerocche J., Mitchell J.D., Leigh P.N., Al-Chalabi A., Miller C.C., Nicholson G., Shaw C.E. TDP-43 mutations in familial and sporadic amyotrophic lateral sclerosis. *Science*, **319**: 1668-1672, 2008.
- Stout J.C., Ready R.E., Grace J., Malloy P.F., Paulsen J.S. Factor analysis of the frontal systems behavior scale (FrSBe). *Assessment*, **10**: 79-85, 2003.
- Strong M.J., Grace G.M., Orange J.B., Leeper H.A., Menon R.S., Aere C. A prospective study of cognitive impairment in ALS. *Neurology*, **53**: 1665-1670, 1999.
- Strong M.J., Lomen-Hoerth C., Caselli R.J., Bigio E.H., Yang W. Cognitive impairment, frontotemporal dementia, and the motor neuron diseases. *Ann. Neurol.*, **54**: S20-23, 2003.
- Strong M.J., Grace G.M., Freedman M., Lomen-Hoerth C., Woolley S., Goldstein L.H., Murphy J., Shoesmith C., Rosenfeld J., Leigh P.N., Bruijn L., Ince P., Figlewicz D. Consensus criteria for the diagnosis of frontotemporal cognitive and behavioural syndromes in amyotrophic lateral sclerosis. *Amyotroph. Lateral Scler.*, **10**: 131-146, 2009.
- Stukovnik V., Zidar J., Podnar S., Repovs G. Amyotrophic lateral sclerosis patients show executive impairments on standard neuropsychological measures and an ecologically valid motor-free test of executive functions. *J. Clin. Exp. Neuropsychol.*, **24**: 1-15, 2010.
- Talbot P.R., Goulding P.J., Lloyd J.I., Snowden J.S., Neary D., Testa H.J. Inter-relation between "classic" motor neuron disease and frontotemporal dementia: neuropsychological and single photon emission computed tomography. *J. Neurol. Neurosurg. Psychiatry*, **58**: 541-547, 1995.
- The Lund and Manchester Groups. Clinical and neuropathological criteria for frontotemporal dementia. *J. Neurol. Neurosurg. Psychiatry*, **57**: 416-418, 1994.
- Ticozzi N., Silani V., LeClerc A.L., Keagle P., Gellera C., Ratti A., Taroni F., Kwiatkowski T.J.Jr, McKenna-Yasek D.M., Sapp P.C., Brown R.H.Jr, Landers J.E. Analysis of FUS gene mutation in familial amyotrophic lateral sclerosis within an Italian cohort. *Neurology*, **73**: 1180-1185, 2009.
- Ticozzi N., Tiloca C., Morelli C., Colombrita C., Poletti B., Doretti A., Maderna L., Messina S., Ratti A., Silani V. Genetics of Familial Amyotrophic Lateral Sclerosis. *Arch. Ital. Biol.*, **149**: 65-82, 2011 (this issue).
- Tronconi V. Sindrome demenziale presenile e sclerosi laterale amiotrofica. *Riv. Sper. Freniatr. Med. Leg.*, **65**: 811-813, 1941.
- Tsuji-Akimoto S., Hamada S., Yabe I., Tamura I., Otsuki M., Kobashi S., Sasaki H. Writing errors as a result of frontal dysfunction in Japanese patients with amyotrophic lateral sclerosis. *J. Neurol.*, **257**: 2071-2077, 2010.
- Valdmanis P.N., Dupre N., Bouchard J.P., Camu W., Salachas F., Meininger V., Strong M., Rouleau G.A. Three families with amyotrophic lateral sclerosis and frontotemporal dementia with evidence of linkage to chromosome 9p. *Arch. Neurol.*, **64**: 240-245, 2007.
- Vance C., Rogelj B., Hortobágyi T., De Vos K.J., Nishimura A.L., Sreedharan J., Hu X., Smith B., Ruddy D., Wright P., Ganesalingam J., Williams K.L., Tripathi V., Al-Saraj S., Al-Chalabi A., Leigh P.N., Blair I.P., Nicholson G., de Bellerocche J., Gallo J.M., Miller C.C., Shaw C.E. Mutations in FUS, an RNA processing protein, cause familial amyotrophic lateral sclerosis type 6. *Science*, **323**: 1208-1211, 2009.
- Van Deerlin V.M., Leverenz J.B., Bekris L.M., Bird T.D., Yuan W., Elman L.B., Clay D., Wood E.M., Chen-Plotkin A.S., Martinez-Lage M., Steinbart E., McCluskey L., Grossman M., Neumann M., Wu I.L., Yang W.S., Kalb R., Galasko D.R., Montine T.J., Trojanowski J.Q., Lee V.M., Schellenberg G.D., Yu C.E. TARDBP mutations in amyotrophic

- lateral sclerosis with TDP-43 neuropathology: a genetic and histopathological analysis. *Lancet Neurol.*, **7**: 409-416, 2008.
- Van Reeth P.C., Perier O., Coers C., Van B.L. Pick's dementia associated with atypical amyotrophic lateral sclerosis. (Anatomoclinical study). *Acta Neurol. Belg.*, **61**: 309-325, 1961.
- Vercelletto M., Bertout C., Geffriaud J., Labat J.J., Magne C., Fève J.R. Dementia de type frontal et sclérose latérale amyotrophique. Trois cas avec étude en tomographies d'émission monophotonique (HmPAO Tc<sup>99m</sup>). *Rev. Neurol.*, **151**: 640-647, 1995.
- Vercelletto M., Ronin M., Huvet M., Magne C., Fève J.R. Frontal type dementia preceding amyotrophic lateral sclerosis: a neuropsychological and SPECT study of five clinical cases. *Eur. J. Neurol.*, **6**: 295-299, 1999.
- Von Braunmühl A. Picksche Krankheit und amyotrophische Lateralsklerose. *Allgemeine Z. Psychiatr. Psychol. Med.*, **96**: 364-366, 1932.
- Wechsler I.S. and Davison C. Amyotrophic lateral sclerosis with mental symptoms. *Arch. Neurol. Psychiatry*, **27**: 859-880, 1932.
- Whitwell J.L., Jack C.R.Jr, Senjem M.L., Josephs K.A. Patterns of atrophy in pathologically confirmed FTLN with and without motor neuron degeneration. *Neurology*, **66**: 102-104, 2006.
- Williams G.B., Nestor P.J., Hodges J.R. Neural correlates of semantic and behavioural deficits in frontotemporal dementia. *Neuroimage*, **24**: 1042-1051, 2005.
- Wolley S.C. and Katz J.S. Cognitive and Behavioral Impairment in Amyotrophic Lateral Sclerosis. *Phys. Med. Rehabil. Clin. N. Am.*, **19**: 607-617, 2008.
- Zago S., Poletti B., Corbo M., Adobbati L., Silani V. Dysgraphia in patients with primary lateral sclerosis: a speech-based rehearsal deficit? *Behav. Neurol.*, **19**: 169-175, 2008.
- Ziegler L.L. Psychotic and emotional phenomena associated with amyotrophic lateral sclerosis. *Arch. Neurol. Psychiatry*, **24**: 930-937, 1930.